

## Spinal Malformation and Syringomyelia in a Calf

Hilal ÇEŞME<sup>1</sup>

Volkan İPEK<sup>2</sup>

Ahmet AKKOÇ<sup>2</sup>

Hakan SALCI<sup>1</sup>

**Abstract:** A Holstein breed, female, one-month-old calf was presented to our clinic with the complaint of congenital astasia on the hind limbs. The vital parameters of the calf were normal, but she was not standing steadily. In palpation, spinal processes of T<sub>10</sub>-L<sub>2</sub> vertebral segments were felt as deformed. Neurologically, there were sensible reflexes, but motor responses were weak bilaterally. In the radiological examination, the irregular intervertebral areas, synostosis on the spinal process and vertebral scoliosis were remarked between T<sub>10</sub>-L<sub>2</sub> segments. Informing the weak prognosis of the calf to the patient owner, she was euthanized after permission. At necropsy, synostosis together with mild scoliosis, and cavitation placed was observed in the spinal process of T<sub>10</sub>-L<sub>2</sub>. About 6cm a transversal enlargement and collapse were seen in the spinal canal. A cystic cavitation about 1 cm in width was identified in the trans-section of this area.

Microscopically, foramen centrale was separated from this cavitation. There was no distinctive cell forming and inflammatory infiltrations in the internal surface of the cavitation. As a result of clinical, radiological and pathologic examinations, spinal malformation and syringomyelia were diagnosed.

**Key Words:** Calf, spinal malformation, syringomyelia.

## Bir Buzağıda Vertebral Malformasyon ve Siringomiyeli

**Özet:** Holstein ırkı, bir aylık dişi bir buzağı doğuştan arka ayakları üzerinde duramama şikayeti ile kliniklerimize getirildi. Buzağının vital parametreleri normaldi ancak ayakta duramamaktaydı (astazi). Palpasyonda, columna vertebralisin T<sub>10</sub>-L<sub>2</sub> arasındaki prosesus spinosusları düzensiz hissedildi. Nörolojik olarak, bilateral duyuşal tepkiler vardı ancak motor refleksler bilateral azalmıştı. Radyolojik muayenede, T<sub>10</sub>-L<sub>2</sub> vertebral segmentlerin intervertebral aralıklarında düzensizlik, prosesus spinosuslarda sinostoz ve vertebral skoliyoz tespit edildi. Prognozun olumsuz olduğu düşüncesi hasta sahibine aktarılarak alınan izin sonrası buzağının ötenazisi gerçekleştirildi. Nekropside T<sub>10</sub>-L<sub>2</sub> vertebral segmentlerin processus spinosuslarında skoliyoz ve sinostoz ile birlikte kavitasyon belirlendi. Spinal kanalda yaklaşık 6 cm'lik bir transversal genişleme ve kollaps görüldü. Bu bölgenin enine kesitinde 1cm genişliğinde kistik kavitasyon görüldü. Mikroskopik olarak foramen centrale bu kavitasyondan ayrıydı. Kavitasyonun iç yüzeyinde belirgin hücre yapısı ve yangısal infiltrasyon da yoktu. Klinik, radyolojik ve patolojik incelemeler sonucu olgumuzda spinal malformasyon ve siringomiyeli tanısı konuldu.

**Anahtar Sözcükler:** Buzağı, vertebral malformasyon, siringomiyeli.

<sup>1</sup> Uludag University, Faculty of Veterinary Medicine, Department of Surgery 16059, Bursa-TURKEY  
hsalci@uludag.edu.tr

<sup>2</sup> Uludag University, Faculty of Veterinary Medicine, Department of Pathology, 16059, Bursa-TURKEY

## Introduction

Malformations of spine are commonly encountered in animals<sup>1</sup>. These usually occur in the thoracolumbar region<sup>10</sup>. Genetic predisposition, nutritional and environmental problems, infectious agents (Akabane, Schmallenberg virus (SBV), bovine viral diarrhea, blue tongue, cache valley etc.) infections, some toxins and fertilization techniques are the reported causes of the congenital malformations in calves<sup>1,10</sup>.

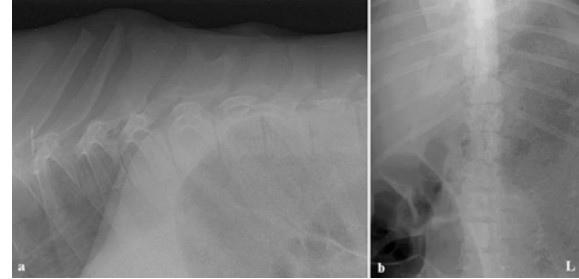
Syringomyelia is a congenital malformation of the spine that it mostly results from the neural tube defects<sup>1,8</sup>. It develops outside the central spinal canal, and the cyst is covered by glia cells<sup>1</sup>. The term of syringomyelia refers to a cystic, fluid filled tubular cavity (syrinx) within the spinal cord extending over several segments<sup>1,2,6-9</sup>. But, it can be acquired after alterations of cerebrospinal fluid pressure, following rupture of a hydromyelia, trauma, neoplasia or inflammation<sup>1,4,7,8</sup>. Additionally, it can be resulted from caudal fossa abnormality (Chiari malformation) and arachnoiditis<sup>2,6,7</sup>. Syringomyelia has been reported in Cavalier King Charles Spaniels but occurs in other mammals such as horses, cattle and camels<sup>1,2,5-7,10</sup>. This pathology has rarely been diagnosed in near past, but it is commonly diagnosed because of increased availability of the diagnostic imaging techniques<sup>1,7</sup>. Clinical, radiological and pathologic examination results of the vertebral malformation and syringomyelia were demonstrated with this case.

### Case Description

Holstein breed, female, one-month-old calf was presented with the complaint of unable to standing steadily (astasia) after birth to the Uludag University, Faculty of Veterinary Medicine and Department of Surgery Clinics. The calf was brought to a Holstein farm and had obtained by an artificial insemination. There had no encountered congenital malformation in the farm up to now. It was also reported that parturition of the calf was normal and in good condition, and vaccination was performed against to BVDV in the farm.

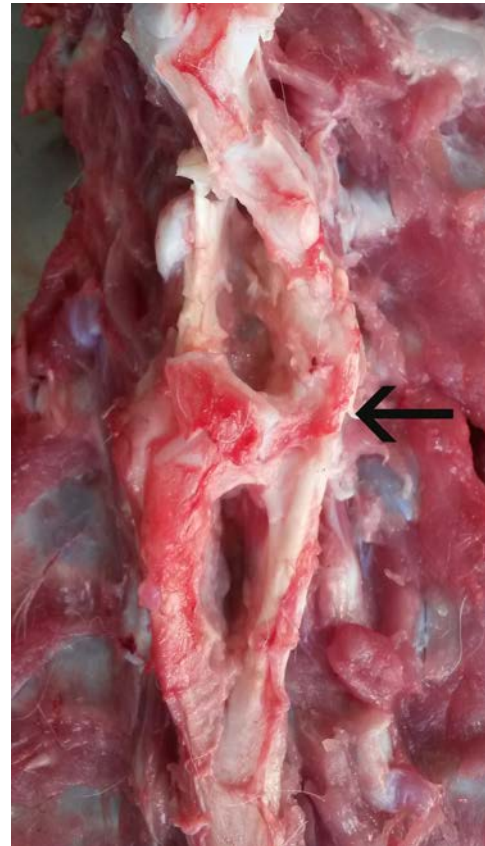
In physical examination, the calf was healthy but she couldn't stand to hind limbs. When hind limbs were supported manually, she could move using front limbs. She was not move by herself. Because of chronical lying, left sides of the hind limbs and caudal abdomen

were wet and there were some decubital wounds. She had scoliosis at thoraco-lumbar region, as well. In palpation of vertebral column, there was an abnormal spinal process formation between T<sub>10</sub>-L<sub>2</sub> segments. Muscles of the hind limbs were atrophic bilaterally.



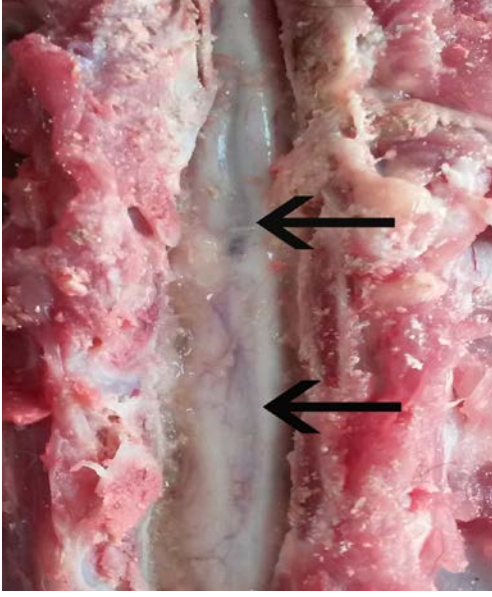
**Figure 1.** Lateral (a) and ventrodorsal (b) radiographs show that irregular intervertebral areas, sinostosis of the spinal process and vertebral scoliosis between T<sub>10</sub>-L<sub>2</sub> segments, (L: left).

**Şekil 1.** Lateral (a) ve ventrodorsal (b) radyografiler T<sub>10</sub>-L<sub>2</sub> segmenti arasında düzensiz intervertebral alanları, spinal proseslerde sinostosis ve vertebral skoliyozu göstermektedir (L: sol).



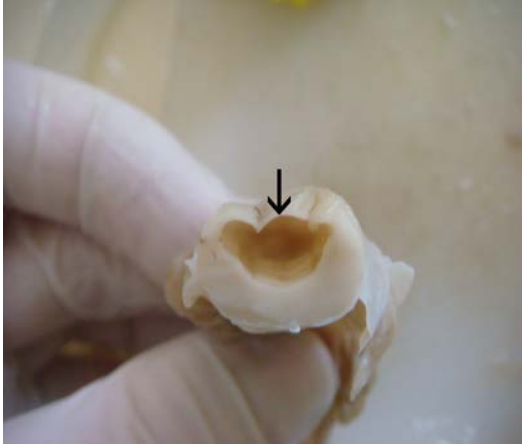
**Figure 2.** Synostosis with cavitations on the dorsal surface of vertebrae (arrow).

**Şekil 2.** Vertebranın dorsal yüzünde kavitasyon ile sinostosis (ok).



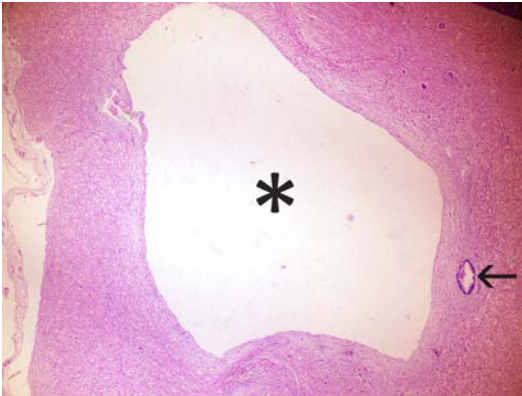
**Figure 3.** Enlargement and collapse in the middle part of spinal cord (arrows).

**Şekil 3.** Spinal kordun orta hattında genişleme ve kollaps (oklar).



**Figure 4.** Cavitation in the spinal cord (arrow).

**Şekil 4.** Spinal kord içindeki kavitasyon (ok).



**Figure 5.** Histopathological sections of the cavitation (asterisk) separated from foramen centrale (arrow), H&E, x40.

**Şekil 5.** Kavitasyonun histopatolojik kesiti (yıldız), ayrı foramen centrale (ok), H&E, x40.

Neurological examination revealed that cranial and peripheral nerves had normal functions, but withdrawing reflex was weak in the hind limbs.

Radiologically, irregular intervertebral areas, sinostosis of the spinal process and vertebral scoliosis were determined between T<sub>10</sub>-L<sub>2</sub> segments in lateral and ventrodorsal radiographs (Figure 1a-b), Informing the weak prognosis and taking to the permission from patient owner, the calf was euthanized by decapitation. At necropsy, synostosis with mild scoliosis and cavitation placed in spinal processes of the T<sub>10</sub>-L<sub>2</sub> segments were observed (Figure 2). After removing dorsal parts of these vertebrae, transversal enlargement and collapse, approximately 6 cm in length, were noticed on the spinal cord (Figure 3). In cross sections, there was a cystic cavitation, approximately 1 cm in diameter, close to dorsum and a thin layer covering to this space (Figure 4).

In the histopathological examination, central nervous system samples were taken into 10% formalin and then following to routine processes, tissues were paraffin-embedded, sectioned at 3 µm thickness and stained with hematoxylin & eosin (H&E). Under the light microscope, a cavitation involves both grey and white matter was seen in the spinal cord (Figure 5). Foramen centrale was intact from the cavitation separately. There was no lining cell layer on the internal surface of the cavity. Some degenerative and necrotic neuronal cells were noticed without any glial activation or inflammation.

## Discussion

In cattle, cerebellar and vertebral malformation induced by BVDV in uterine life is well-documented. Furthermore BTV and SBV cause vertebral malformation in large populations<sup>1</sup>. Thus, we asked for the patient owner and learned from that vaccination against to BVDV had been administered in the farm.

Syringomyelia often combines to additional disorders such as Dandy-Walker Syndrome, scoliosis, cleft palate, Arnold-Chiari like malformation, dicephalus, spinal dysraphism, hydromyelia, aplasia or hypoplasia of the spinal cord, diplomyelia, aberrations of the central canal<sup>1,3,5-7</sup>. Clinically, these abnormalities can be difficult to separate from other causes of spinal cord disease without skeletal abnormalities<sup>1</sup>.

The clinical appearance of the spinal malformations is similar to spinal trauma which can have bone fractures and epidural or intraspinal hemorrhage pointing out the spinal injury<sup>1</sup>. As determined in some congenital malformations, pathophysiological mechanism of the syringomyeli and hydromyelia is not clearly known yet<sup>7,9</sup>. Syringomyelia is the spinal cord malformation that occurs acquired or congenital at dogs, horses and camels. In general, clinical symptom is that newborn calves are not able to rise or have incoordination at hind limbs. This presented case was a new born Holstein calf with inability to rise of the hind limbs due to syringomyelia. It is difficult to diagnose syringomyelia by the help of clinical, neurological and radiological examination. Advanced diagnostic techniques such as magnetic resonance imaging are necessary to exact and differential diagnosis for hydromyelia and syringomyelia<sup>1,7,9</sup>. In presented case, clinical findings were related to neuroanatomical region problems effecting spinal cord. In addition, although ultrasonographic examinations recommend due to practical diagnostic technique for veterinary practitioner in living animals<sup>1</sup>, we did not perform this technique following to radiological examination. The exact diagnosis of our case according to pathological examinations was spinal malformation and syringomyelia.

Edema, neuronal cell shrinkage, axon swelling, necrosis, gliosis or capillary proliferation is remarkable in spinal trauma at histological examination<sup>1</sup>. Etiology of the presented case was congenital, thus we did not encounter any microscopic findings of trauma. Histopathologically, the diagnosis of the presented calf was spinal malformation and syringomyelia.

## References

1. Burgstaller, J., Thaller, D., Leeb, T., Schlesinger, P., Köfler, J. 2015. Syringomyelia in a newborn male simmental calf. *J Vet Intern Med*, 29(6), 1633-1637.
2. Freeman A.C., Platt S.R., Kent, M., Huguet, E., Rusbridge, C., Holmes, S. 2014. Chiari-Like Malformation and syringomyelia in American brussels griffon dogs. *J Vet Intern Med*, 28(5), 1551-1559.
3. Gülbahar, M.Y., Yüksel, H., Soyguder, Z., Ercin, Ö.F. 2005. Dicephalus, Arnold-Chiari malformation, spinal dysraphism and other associated anomalies in a newborn Holstein calf. *Turk J Vet Anim Sci*, 29, 565-570.
4. Imai, S., Moritomo, Y. 2009. Segmental hypoplasia of the spinal cord in a Japanese black calf. *J Vet Med Sci*, 71(3): 337-340.
5. Ohfuji, S. 1999. Spinal dysraphism in a newborn Holstein-Friesian calf. *Vet Pathol*, 36(6), 607-609.
6. Rusbridge, C. 2007. Chiari-Like malformation with syringomyelia in the Cavalier King Charles spaniel: long-term outcome after surgical management. *Vet Surg*, 36(5): 396-405.
7. Rusbridge, C., Greitz, D., Iskandar, J.B. 2006. Syringomyelia: current concepts in pathogenesis, diagnosis, and treatment. *J Vet Intern Med*, 20(3), 469-479.
8. Şakamoto, K., Kiupel, M., Frank, N., March, P.A. 2004. Vertebral malformation, syringomyelia, and ventricular septal defect in a dromedary camel (*Camelus dromedarius*). *J Vet Diagn Invest*, 16(4), 337-340.
9. Sponseller, B.A., Sponseller, B.T., Alcott, J.C., Kline, K., Hostetter, J., Reinertsonel, E.L., Fales-Williams, A. 2011. Syringohydromyelia in horses: 3 cases. *Can Vet J*, 52(2), 147-152.
10. Yıldırım, F., Gurel, A., Devencioglu, Y., Eravcı, E., Dönmez, K. 2013. Congenital segmental hypoplasia of the spinal cord in a Holstein calf. *Kafkas Univ Vet Fak Derg*, 19(6), 1049-1052.