

Detecting the Shape Differences of the Corpus Callosum in Behçet's Disease by Statistical Shape Analysis

CEMIL COLAK,^{1*} ILKER ERCAN,² METIN DOGAN,³ SENEM TURAN OZDEMIR,⁴
SERPIL SENER,⁵ AND ALPAY ALKAN³

¹Department of Biostatistics, Faculty of Medicine, Inonu University, Malatya, Turkey

²Department of Biostatistics, Faculty of Medicine, Uludag University, Bursa, Turkey

³Department of Radiology, Faculty of Medicine, Inonu University, Malatya, Turkey

⁴Department of Anatomy, Faculty of Medicine, Uludag University, Bursa, Turkey

⁵Department of Dermatology, Faculty of Medicine, Inonu University, Malatya, Turkey

ABSTRACT

The aim of this study was to assess the shape differences of the corpus callosum (CC) in patients with Behçet's disease using statistical shape analysis (SSA). Additionally, an attempt was made to investigate the changes in CC size according to disease duration. Twenty-five adults with clinically diagnosed Behçet's disease and 25 age- and gender-matched controls were examined by high-resolution structural magnetic resonance imaging. The data obtained from the coordinate of landmarks were analyzed with Euclidean distance matrix analysis and a thin-plate spline analysis. SSA and growth curve models were performed to investigate group differences and to fit the curves. A significant difference was determined between CC shape of Behçet patients and controls ($P = 0.006$). Based on the analysis, a decrease occurred in the CC size of the Behçet patients as the duration of disease increased. Maximum deformations were determined in the landmarks of interior notch of the splenium, inferior tip of the splenium, posterior-most point of the CC, and topmost point of the CC. Similarly, the landmark of anterior-most point of the CC was identified as having the minimum deformation. Behçet patients had significantly different CC shapes from control subjects. The results suggest that SSA is a promising tool for distinguishing Behçet patients from normal subjects, and that it can give useful information to assist clinicians. Additionally, SSA might be applied to detect shape differences in anatomical structures that are affected by a broad range of neurological diseases. *Anat Rec*, 294:870–874, 2011. © 2011 Wiley-Liss, Inc.

Key words: Behçet's disease; corpus callosum; geometric morphometrics; growth curve models; statistical shape analysis

Behçet's disease is a multisystem inflammatory condition with the classic triad of aphthous stomatitis, uveitis, and urogenital ulcerations. Behçet's disease is a chronic, relapse-remitting, occlusive vasculitis affecting multiple organ systems in the body. It is common in the Mediterranean basin countries, the Middle East, and eastern Asia (Serdaroglu, 1998; Davatchi et al., 2010). The prevalence of Behçet's disease is known to be particularly high in Japan and Turkey (5.3%–7.6%)

*Correspondence to: Cemil Colak, Department of Biostatistics, Faculty of Medicine, Inonu University, Malatya, Turkey. Fax: +90 422 3410036. E-mail: cemilcolak@yahoo.com

Received 11 November 2010; Accepted 3 February 2011

DOI 10.1002/ar.21373

Published online 31 March 2011 in Wiley Online Library (wileyonlinelibrary.com).

(Serdaroglu, 1998). Neurological involvement is well defined in Behçet's disease, the prevalence of which was reported to be between 2.2% and 50% (Al-Fahad and Al-Araji, 1999). Brain stem or corticospinal way syndromes are often reported as neurological involvement depending on venous sinus thrombosis or aseptic meningitis due to increased intracranial pressure (Koçer et al., 1999).

Many studies indicate that the corpus callosum (CC) size and shape are related to gender, age, and neurodegenerative diseases, among other factors (Ozdemir et al., 2007). In addition, a study identified significant shape differences of the CC in patients with autism and control subjects between the landmark configurations in terms of the deformation from the overall mean configuration (He et al., 2010). The shape differences of the CC in patients with Behçet's disease have not been investigated by a landmark-based method. To our knowledge, this study evaluates the shape differences of CC for Behçet patients for the first time using a landmark-based geometrical morphometric method, statistical shape analysis (SSA).

SSA compares body forms by using specific landmarks determined by anatomical prominences. Geometric morphometrics is a landmark-based method that was developed to analyze form and thus morphological changes (Ozdemir et al., 2010). The quantitative morphological assessment of individual brain structures is often based on global volume and area measurements, which are intuitive features that may explain atrophy or dilation due to illness. On the other hand, structural changes at specific locations are not sufficiently reflected in volume and area measurements. Shape analysis has thus become of increasing interest to the neuroimaging community (Bookstein, 1991; Richtsmeier et al., 1992; Franklin et al., 2005). Many studies have measured anatomical brain structures quantitatively in terms of volume, area, width, and length, but only a few have performed a shape analysis using anatomical landmarks (Ozdemir et al., 2007).

In this study, the aim was to assess the shape differences of the CC in patients with Behçet's disease using SSA. Additionally, an attempt was made to investigate the changes in the size of the CC according to disease duration.

MATERIALS AND METHODS

Subjects

The study was conducted on magnetic resonance imaging (MRI) scans of 25 Behçet patients [age: 43.4 ± 9.3 year old (29–59); mean \pm SD (min–max)] and 25 control subjects matched by gender and age. MRI scans of consecutive Behçet patients who were admitted to the Department of Radiology, Faculty of Medicine, Inonu University, were taken retrospectively between May and June 2010. Behçet patients satisfied the criteria for Behçet disease recommended by the International Study Group (ISG) (ISG for Behçet's disease, 1990). Patients who had neurological disorders, diabetes mellitus, hypertension, and so forth were excluded from the study. This retrospective study was approved by the institutional review board, and all participants gave informed consent before the start of the study. The mean duration of Behçet's disease was 7.6 ± 3.9 years (2–16) [mean \pm SD (min–max)].

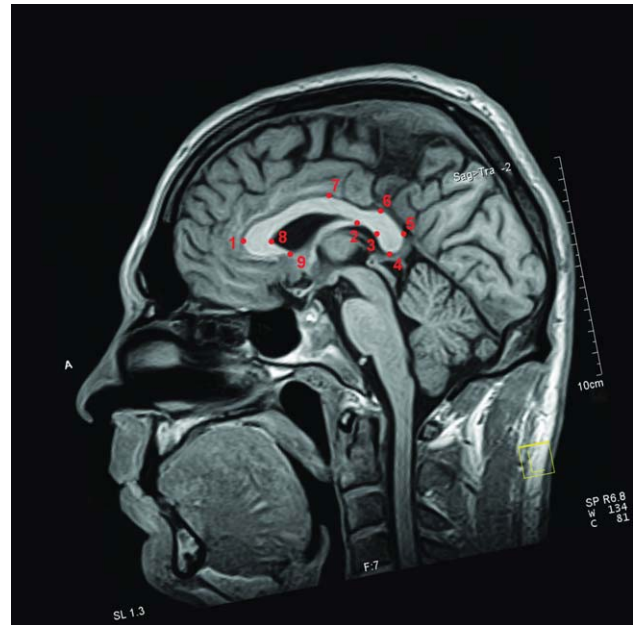


Fig. 1. The landmarks that were utilized in the statistical shape analysis.

MRI Examinations

With regard to the MRI examinations, all MRI scans were achieved at 1.5 T (Philips Gyroscan Intera., Best, The Netherlands) as sagittal T2-weighted turbo spin echo images (repetition time, 4,366 msec; echo time, 120 msec, excitations: 1). The thickness of the slice was 6 mm, with a skip of 1 mm between slices and a 256×256 matrix.

Collection of Two-Dimensional CC Landmarks

The midsagittal section that most clearly displayed the cerebral aqueduct, CC and superior colliculus was manually selected from the sagittal planes. The anterior to posterior commissure line and interhemispheric fissure were determined and used to align the brains of all subjects to a standard position. In this image, nine landmarks on the CC were defined (Fig. 1): 1, anterior-most point of the CC; 2, CC-fornix junction; 3, interior notch of the splenium; 4, inferior tip of the splenium; 5, posterior-most point of the CC; 6, topmost point of the splenium, 7, topmost point of CC; 8, posterior angle of the genu; and 9, posterior tip of the genu. Table 1 lists the explanation of the anatomical landmarks. The studied landmarks were signed on the digital images by using TPSDIG 2.04 software. The points of these landmarks fall within the criteria outlined in Bookstein (1991) as well as include extreme points, terminals and maxima of curvature, and other local shape processes. The computation is proceeded in four steps. We first identified landmarks from the series of homologous MRI scans and then determined landmark coordinates. Afterward, we clarified the mean landmark configurations of Behçet patients and control subjects and appraised general and local shape differences. In the last step, we determined the shape deformations of Behçet patients compared to

TABLE 1. The explanation of the anatomical landmarks of the corpus callosum

Landmark	Landmark definition
1	Anterior-most point of the CC
2	CC–fornix junction
3	Inferior notch of the splenium
4	Inferior tip of the splenium
5	Posterior-most point of the CC
6	Splenium topmost point
7	Topmost point of the CC
8	Posterior angle of the genu
9	Posterior tip of the genu

CC: corpus callosum.

the controls through the thin-plate spline (TPS) method, using average shapes obtained by Procrustes analysis. The shape deformations of the patients relative to the controls were expressed by utilizing expansion and contraction grids.

Statistical Analysis

A generalized Procrustes analysis was used for evaluating shapes. The homogeneity of variance–covariance matrices was examined using the Box-M test (Dryden and Mardia, 1998). Since the variance–covariance matrices were not homogeneous ($P = 0.006$), James F_J test was used for comparing the shapes (Dryden, 2009; Brombin and Salmaso, 2009).

The shape deformations of the CC were evaluated using a TPS analysis. Procrustes mean shapes were computed for TPS. In accordance with the TPS analysis, the points exhibiting the most enlargements or decreases were labeled as deformations.

To obtain overall measures of shape variability for the Behçet and control subjects, the root mean squares of Kendall's Riemannian distance (ρ) to the mean shape were computed (Dryden, 2009).

The relationships between the centroid sizes and the durations of Behçet's disease in patients with Behçet's disease were examined by the growth curve models of Richards, Logistic, Gompertz, Michaelis–Menten, Bleasdale-Nelder, Monomolecular, and Holliday (Seber and Wild, 1989; Gürcan et al., 2010). Assessing the fit of the models was carried out based on the coefficient of determination (R^2) and root mean squared error (RMSE).

Landmark Reliability

We calculated the intrarater reliability coefficient for a two-facet crossed design (landmark pairs-by-rater-by-subject, $l \times r \times s$) based on the generalizability theory (GT) (Ercan et al., 2008). In GT, the reliability for relative (norm referenced) interpretations is referred to as the generalizability (G) coefficient (Dimitrov, 2006).

In this study, a single rater marked the anatomical landmarks. The reliability of the rater was judged using repeated landmarks on groups. Specifically, nine landmarks were marked by the same investigator, and after a month, the same investigator marked the same landmarks on all of the images again. The analysis of the rating indicated good repeatability ($G = 0.9968$).

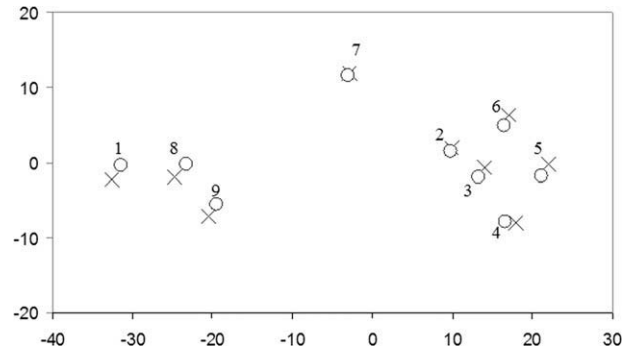


Fig. 2. Procrustes mean shapes for corpus callosum images of Behçet patients and controls (Cases: X, Controls: O).

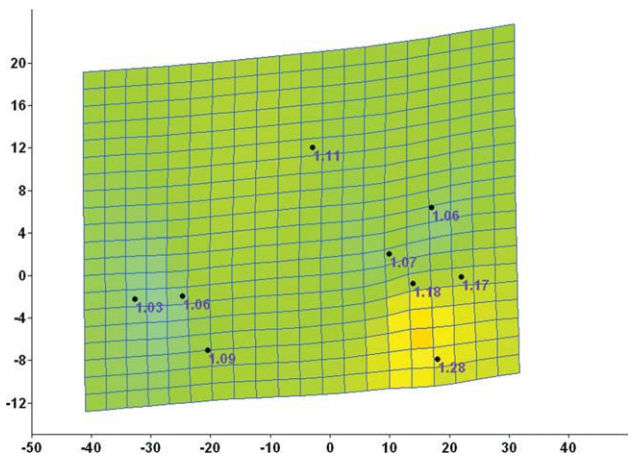


Fig. 3. Thin-plate spline demonstrating average shape deformation from controls to Behçet cases. Expansion factors at the landmarks are shown numerically (expansion factors larger than one).

RESULTS

Out of 25 Behçet patients in the study, 11 (44%) were female, and the remaining 14 patients (56%) were male. A significant difference was determined between CC shape of Behçet patients and controls ($P = 0.006$) (Fig. 2). Shape deformations were observed from the controls to the patients (Fig. 3). Maximum deformations were determined in the landmarks of inferior notch of the splenium, inferior tip of the splenium, posterior-most point of the CC, and topmost point of the CC. Similarly, the landmark of anterior-most point of the CC was identified as having the minimum deformation. Variabilities according to the general CC shape in Behçet cases and controls were 0.067 and 0.072, respectively. Similarities were observed in terms of shape variability.

Figure 4 demonstrates the relationship between the centroid sizes and the durations of Behçet's disease in Behçet patients. Among the models setting out the studied relationship, the Michaelis–Menten model was the most appropriate model based on the coefficient of determination and RMSE as described in Table 2. From the results of the modeling, R^2 and RMSE were 0.13 and

6.24, respectively. When Fig. 4 is viewed, a decrease occurs in the CC size of the Behçet patients as the duration of disease increases.

DISCUSSION

SSA is of increasing interest to the neuroimaging community because of its potential to locate morphological changes. Statistical studies of anatomical shape variations in populations are important for understanding the anatomical effects of diseases or biological processes (Polina et al., 2001). Several procedures for obtaining shape information from landmark data have been proposed (Richtsmeier, 1992; Ozdemir et al., 2007; Ercan et al., 2008). Local shape analysis has gained more interest recently due to its potential to locate shape morphologies. Landmark-based methods have been popular in shape analysis because of the belief that evaluating general form differentiation in the shape by using neuroanatomical landmarks is most relevant (Ozdemir et al., 2007). In this study, the landmark-based shape data of the CC was analyzed in both Behçet patients and controls. Hence, we implemented a Procrustes analysis by using homologous anatomical landmarks, which are most relevant. Thus, to our knowledge, this study is the first where CC shape differences were evaluated for Behçet patients using a landmark-based geometrical morphometric method. We used nine landmarks on the CC for shape analysis and found differences between the shape means of the two groups.

Ozdemir et al. (2007) proposed that future studies on shape alterations of the CC could be associated with certain medical conditions. Based on this result, we conducted this study to discriminate Behçet patients from

controls on the basis of shape differences. As a result of our investigations on the shape of CC, we defined significant differences between Behçet patients and control subjects from the results of the SSA. However, the general shape variability of the CC in Behçet patients and control subjects was the same.

The TPS method is sufficient to describe the deformations that may be encountered in medical scans and used effectively for modeling coordinate transformations in image-based applications (Murphy et al., 2010). Recently, a study identifying the shape differences of the CC between autism patients and control subjects using a TPS analysis showed significant group differences between the landmark configurations in terms of the deformation from the overall mean configuration (He et al., 2010). In another study, Ozdemir et al. (2007) identified shape differences of the CC between genders and found significant differences in the distances between some landmarks with the use of TPS analysis. Similarly, the comparison of the Fisher-Rao metric, and the TPS was studied by a pairwise matching of CC shapes (Peter and Rangarajan, 2006). The acquired results of the TPS analysis in this study revealed that the maximum deformations were determined in the landmarks of interior notch of the splenium, inferior tip of the splenium, posterior-most point of the CC, and topmost point of the CC. Similarly, the landmark of anterior-most point of the CC was identified as having the least deformation. To our knowledge, the only study published on both Behçet's disease and the CC reported that high-signal MRI lesions of the CC in the T₂-weighted MRI image were consistent with the diagnosis of neuro-Behçet's disease (Lackmann et al., 2004). However, the etiology of Behçet's disease and its influences on the shape of the CC remain unknown.

The presence of the most prominent global shape variability in the anterior lower body and posterior bottom of the CC was observed using similar methods and landmarks for autistic patients in a reported study. Again, local shape variability was found in the anterior bottom (He et al., 2010).

The quality of life of patients (Behçet's disease occurred in 15% of patients) is significantly related to disease duration (Miserocchi et al., 2010). This reported result is consistent with our results. It is observed that a decrease occurs in the CC sizes of the Behçet patients as the duration of the disease increases.

Baysal et al. (2003, 2005) determined differences in the apparent diffusion coefficient values of Behçet patients by means of diffusion-weighted MR imaging and magnetic resonance spectroscopy in the brain regions when structural changes are absent. According to their findings, they identified microstructural changes caused by vasculitis. Also, our study detected a decrease in the size of the CC in proportion to the duration of the disease in Behçet's patients with brains that were

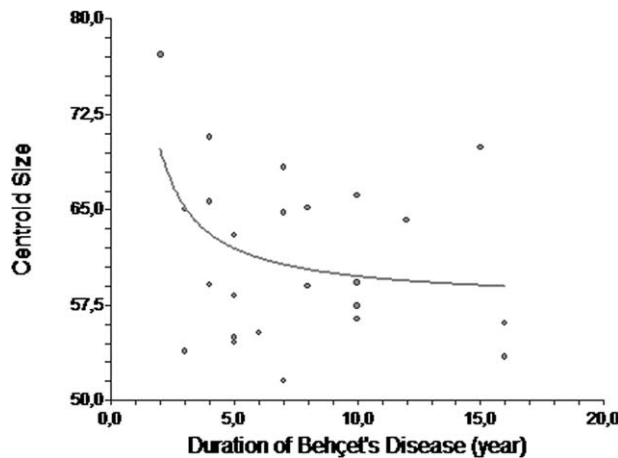


Fig. 4. The relationship between CC size and the duration of Behçet's disease in Behçet patients.

TABLE 2. The modeling of the relationship of CC size with disease duration

The relationship	The most appropriate Model*	Predicted Equation	R^2	RMSE
CC size-disease duration in patients	Michaelis-Menten	$CS = \frac{[(56.67)(DD)]}{[(-0.34) + (DD)]}$	0.13	6.24

CS, centroid size; DD, duration of disease; CC, corpus callosum; R^2 , the coefficient of determination; RMSE, root mean squared error; * $P < 0.05$.

macroscopically normal in appearance. Similar to the results of Baysal et al. (2003, 2005), our results may indicate that the microstructural changes in the CC could be due to vasculitic injury to interhemispheric, transcallosal fiber tracks.

To sum up our findings, Behçet patients had significantly different CC shapes from control subjects. Based on the results of the analysis, the CC sizes of the Behçet patients decreased as the durations of disease increased. The results obtained suggest that SSA is a promising tool for distinguishing Behçet patients from normal subjects, and that it can give useful information to assist clinicians. Additionally, this method might be applied to detect shape differences in anatomical structures that are affected by a broad range of neurological diseases.

LITERATURE CITED

- Al-Fahad AS, Al-Araji AH. 1999. Neuro-Behçet's disease in Iraq: a study of 40 patients. *J Neurol Sci* 170:105–111.
- Atkinson M, Moore E, Altinok D, Acsadi G. 2008. Cerebral infarct in pediatric neuro-Behçet's disease. *J Child Neurol* 23:1331–1335.
- Baysal T, Dogan M, Karlidag R, Ozisik HI, Baysal O, Bulut T, Sarac K. 2005. Diffusion-weighted imaging in chronic Behçet patients with and without neurological findings. *Neuroradiology* 47:431–437.
- Baysal T, Ozisik HI, Karlidag R, Sarac K, Baysal O, Dusak A, Hazneci E, Ozcan C. 2003. Proton MRS in Behçet's disease with and without neurological findings. *Neuroradiology* 45:860–864.
- Bookstein FL. 1991. *Morphometrics tools for landmark data*. New York: Cambridge University Press.
- Brombin C, Salmaso L. 2009. Multi-aspect permutation tests in shape analysis with small sample size. *Comput Stat Data Anal* 53:3921–3931.
- Davatchi F, Shahram F, Chams-Davatchi C, Shams H, Nadji A, Akhlaghi M, Faezi T, Sadeghi Abdollahi B. 2010. How to deal with Behçet's disease in daily practice. *Int J Rheum Dis* 13:105–116.
- Dimitrov DM. 2006. Reliability. In: Erford BT, editor. *Assessment for counselors*. Boston: Houghton-Mifflin/Lahaska Press. Chapter 3, pp 99–122.
- Dryden IL. 2009. *Shapes: statistical shape analysis*. R package version 1.1–3. Available at: <http://cran.r-project.org/>. Accessed on 10 June 2010.
- Dryden IL, Mardia KV. 1998. *Statistical shape analysis*. New York: Wiley.
- Ercan I, Ocakoglu G, Guney I, Yazici B. 2008. Adaptation of generalizability theory for inter-rater reliability for landmark localization. *Int J Tomogr Stat* 9:51–58.
- Franklin D, Freedman L, Milne N. 2005. Three-dimensional technology for linear morphological studies: a re-examination of cranial variation in four southern African indigenous populations. *J Comp Hum Biol* 56:17–34.
- Gürçan M, Colak C, Orman MN. 2010. Bernstein polynomial approach against to some frequently used growth curve models on animal data. *Pak J Stat* 26:509–516.
- He Q, Duan Y, Karsch K, Miles J. 2010. Detecting corpus callosum abnormalities in autism based on anatomical landmarks. *Psychiatry Res: Neuroimaging* 183:126–132.
- International Study Group for Behçet's disease. 1990. Criteria for diagnosis of Behçet's disease. *Lancet* 335:1078–1080.
- Koçer N, Islak C, Siva A, Saip S, Akman C, Kantarci O, Hamuryudan V. 1999. CNS involvement in neuro-Behçet syndrome: an MR study. *AJNR Am J Neuroradiol* 20:1015–1024.
- Lackmann GM, Lyding S, Scherer A, Niehues T. 2004. Acute disseminated encephalomyelitis and mucocutaneous ulcerations. *Neuropediatrics* 35:253–254.
- Miserocchi E, Modorati G, Mosconi P, Colucci A, Bandello F. 2010. Quality of life in patients with uveitis on chronic systemic immunosuppressive treatment. *Ocul Immunol Inflamm* 18:297–304.
- Murphy K, van Ginneken B, Klein S, Staring M, de Hoop BJ, Viergever MA, Pluim JP. 2010. Semi-automatic construction of reference standards for evaluation of image registration. *Med Image Anal* doi:10.1016/j.media.2010.07.005.
- Ozdemir ST, Ercan I, Ozkaya G, Cankur NS, Erdal YS. 2010. Geometric morphometric study and cluster analysis of Late Byzantine and modern human crania. *Coll Antropol* 34:493–499.
- Ozdemir ST, Ercan I, Sevinc O, Guney I, Ocakoglu G, Aslan E, Barut C. 2007. Statistical shape analysis of differences in the shape of the corpus callosum between genders. *Anat Rec (Hoboken)* 290:825–830.
- Peter A, Rangarajan A. 2006. A new closed-form information metric for shape analysis. *Med Image Comput Assist Interv* 9(Pt 1):249–256.
- Polina G, Grimson WEL, Shenton ME, Kikinis R. 2001. Deformation analysis for shaped based classification, information processing in medical imaging. In *Proceedings of IPMI: International Conference on Information Processing and Medical Imaging*, LNCS 2082:517–530.
- Richtsmeier JT, Cheverud JM, Lele S. 1992. Advances in anthropological morphometrics. *Annu Rev Anthropol* 21:283–305.
- Seber GAF, Wild CJ. 1989. *Nonlinear regression*. New York: Wiley.
- Serdaroglu P. 1998. Behçet's disease and the nervous system. *J Neurol* 245:197–205.