

Osteochondritis dissecans in a patient with hyperimmunoglobulin E syndrome

S. Şebnem Kılıç¹, Özden Sanal², İlhan Tezcan², Fügen Ersoy²

¹Department of Pediatrics, Uludağ University Faculty of Medicine, Bursa and ²Immunology Unit, Department of Pediatrics, Hacettepe University Faculty of Medicine, Ankara, Turkey

SUMMARY: Kılıç SŞ, Sanal Ö, Tezcan İ, Ersoy F. Osteochondritis dissecans in a patient with hyperimmunoglobulin E syndrome. Turk J Pediatr 2002; 44: 357-359.

Hyperimmunoglobulin E syndrome (hyper-IgE) is a rare immunodeficiency disease associated with recurrent pyogenic infections, chronic eczematoid dermatitis and osteopenia.

We present here a 13-year-old girl with hyperimmunoglobulin E syndrome, who developed osteochondritis dissecans (OCD) of the lateral femoral condyle, which is rare. Osteopenia, which is frequently associated with hyper IgE, may predispose the patient to the development of OCD.

Key words: bone abnormalities, hyperimmunoglobulin E syndrome, osteochondritis dissecans, osteopenia.

The hyperimmunoglobulinemia E (hyper-IgE) syndrome is a rare primary immunodeficiency characterized by markedly elevated serum IgE levels, chronic dermatitis, recurrent sinopulmonary infections, recurrent severe skin abscesses generally caused by *Staphylococcus aureus*, coarse facial features and growth retardation¹. Osteochondritis dissecans (OCD) is a disease characteristically affecting the epiphysis, with subsequent separation and fragmentation of the subchondral bone in association with disruption of the overlying articular cartilage². Although bone abnormalities such as osteopenia and recurrent fractures are present in most patients with the hyper-IgE syndrome, OCD has not been reported yet in these patients.

Here we present a patient having hyper-IgE syndrome who developed osteochondritis dissecans of the lateral condyle of the right femur.

Case Report

The female patient was first admitted to Hacettepe University İhsan Doğramacı Children's Hospital at two years of age with the complaints of recurrent pneumonia, skin abscesses and oral candidiasis. She was the third child of nonconsanguineous parents, and her two

brothers were healthy. Physical examination showed coarse facial appearance (Fig. 1) and multiple skin abscesses. Her serum immunoglobulin G, A, and M levels were normal with an elevated IgE of 2,500 IU (4-269 IU/ml). In vitro lymphocyte proliferative responses to mitogens, neutrophil chemotaxis, and antibody responses to polio antigens were found to be normal. Absolute eosinophil count was 464/mm³. Bone density was found more than two standard deviations below the normal values for age and sex. She was put on prophylactic daily trimethoprim-sulfamethoxazole therapy. Her growth and development were within normal limits and she experienced occasional minor skin abscesses and upper respiratory tract infections during follow-up. At age 11 years, the patient was hospitalised for the treatment of right superior lobe abscess of the lung, and was treated with antistaphylococcal antibiotics.

She was admitted to the hospital with the complaints of pain, swelling and locking on her right knee at 13 years of age. Clinical examination revealed effusion of the right knee. X-rays of the right knee (Fig. 2) showed a fragmentation of the lateral condyle of the femur. The loose body was removed surgically. When she was seen two months after surgical



Fig. 1. Characteristic facial appearance of our patient with hyperimmunoglobulin E syndrome.

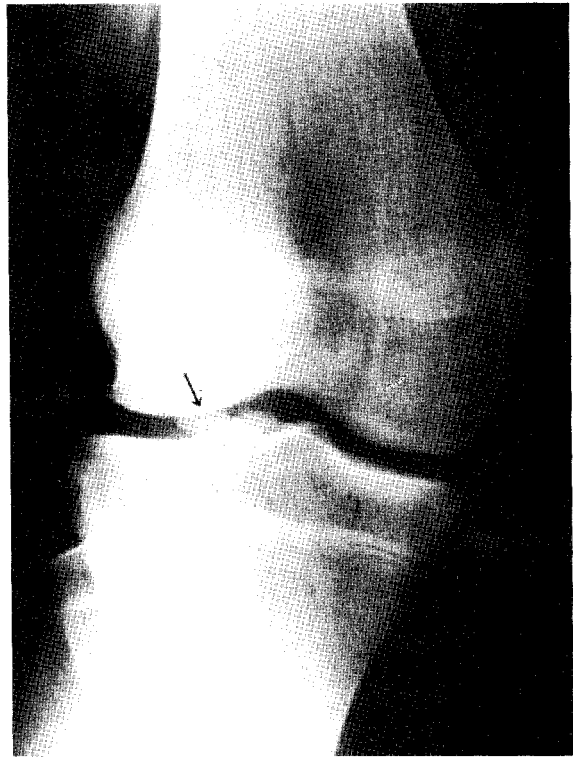


Fig. 2. Plain X-ray showing osteochondritis dissecans of the lateral femoral condyle.

intervention she did not have any complaints and clinical examination was normal. A full range of movement of right knee was possible.

Discussion

Osteochondritis dissecans (OCD) has been called "quiet necrosis". The peak frequency occurs during the teenage years, with a mean age of 15 years. The frequency in males has been reported to be two or three times more than that of females³. The right knee is involved slightly more often than the left, and in 7-25% of cases the lesion is bilateral⁴. All prior reports have documented that the intercondylar aspect of the medial femoral condyle was the predominant site of this lesion, with osteochondritis in the lateral condyle accounting for approximately 15-20% of all affected knees⁵. The clinical management of OCD depends largely on the mechanical stability of the osteochondral fragment. Surgical removal or internal fixation of the fragment is indicated when the lesion is diagnosed before or after epiphyseal closure and there is objective

evidence of looseness of the fragment as well as functional disability⁶. Surgical treatment relieved the symptoms in our patient

There are many theories regarding the cause of the disease, and ischemic necrosis, trauma, congenital alterations in bone or cartilaginous development (or both), endocrine alterations (Fröhlich's syndrome, thyroid or sex hormone abnormalities) and genetic predisposition have been implicated³. We could not detect any trauma history, genetic predisposition or endocrine abnormalities in our patient.

In Lindholm's series⁷, osteoporosis was observed in three out of 20 patients with OCD. One of them had immobilization for four months; the others had osteonecrosis due to continuous corticosteroid therapy or chronic alcoholism. None of the reported risk factors was presented in our patient but she was diagnosed as hyper-IgE syndrome associated with osteopenia. Leung et al.⁸ suggested that monocytes from patients with hyper-IgE syndrome are activated to resorb bone via products of the prostaglandin synthase

(cyclooxygenase) pathway. The activation of cells in the monocyte-macrophage family to resorb bone may contribute to osteopenia observed in hyper-IgE syndrome. Fifty-seven percent of the patients with hyper-IgE have bone fractures⁹. It seems that osteopenia caused by hyper-IgE syndrome is a favourable etiologic factor of OCD.

Both pediatricians and orthopedists caring for patients with hyper-IgE syndrome should be aware of the associated bone abnormalities.

REFERENCES

1. Buckley RH, Wray BB, Belmaker EZ. Extreme hyperimmunoglobulinemia E and undue susceptibility to infections. *Pediatrics* 1972; 49: 59-70.
2. Yoshida S, Ikata T, Takai H, Kashiwaguchi S, Katoh S, Takeda Y. Osteochondritis dissecans. *Clin Orthop* 1998; 346: 162-170.
3. Schenck RC, Goodnight JM. Osteochondritis dissecans. *J Bone and Joint Surg* 1996; 78: 439-456.
4. Linden B. The incidence of osteochondritis dissecans in the condyles of the femur. *Acta Orthop Scand* 1976; 47: 664-667.
5. Green W, Banks HH. Osteochondritis dissecans in children. *J Bone Joint Surg* 1953; 35: 26-47.
6. Hughston JC, Hergenroeder PT, Coutenay BG. Osteochondritis dissecans of the femoral condyles. *J Bone Joint Surg* 1984; 66: 1340-1348.
7. Lindholm S, Pylkkänen P, Österman K. Fixation of osteochondral fragments in the knee joint. *Clin Orthop* 1976; 126: 256-260.
8. Leung DY, Key L, Steinberg JJ, et al. Increased in vitro bone resorption by monocytes in the hyperimmunoglobulin E syndrome. *J Immunol* 1988; 140: 84-88.
9. Grimbacher B, Holland SM, Gallin JL, et al. Hyper-Ig E syndrome with recurrent infections an autosomal dominant multisystem disorder. *N Engl J Med* 1999; 340: 692-702.