

Descending necrotizing mediastinitis: increased mortality due to delayed presentation

Mehmet Muharrem EROL¹, Ahmet URAL², Hüseyin MELEK¹, Ahmet Sami BAYRAM¹, Celal TEKİNBAŞ³,
Cengiz GEBİTEKİN¹

Aim: To describe the clinical features of descending necrotizing mediastinitis (DNM) and to outline the diagnostic and therapeutic measures to be taken in its management.

Materials and methods: We retrospectively analyzed the data from 13 patients with DNM treated between 2001 and 2012 in 2 tertiary care centers, together with their demographics, diagnostic methods, therapeutic interventions, and clinical outcomes.

Results: The patients consisted of 10 males and 3 females, aged from 16 to 72 years (mean age: 44). Odontogenic and tonsillar infections were the probable sources of infection in the majority of cases. Computerized tomography is a crucial imaging modality in the diagnosis and follow-up of patients with DNM. All patients underwent surgical treatment in addition to intravenous broad-spectrum antibiotics. Tube thoracostomy, mediastinal drainage, cervical drainage, and thoracotomy were the therapeutic measures utilized in these patients. Five patients were lost (38%) and 8 survived.

Conclusion: DNM is a life-threatening condition that may originate from oropharyngeal infections. Emergency surgical intervention is mandatory in the management of DNM. The 2 most important survival factors are early surgical intervention and adequate drainage.

Key words: Mediastinitis, necrotizing, emergency

Introduction

Acute mediastinitis is a potentially fatal condition that may occur due to oropharyngeal infections or esophageal perforations, or after cardiothoracic surgery (1). Descending necrotizing mediastinitis (DNM) is a form of acute mediastinitis originating from the spread of oral/oropharyngeal infection to the mediastinum via the pretracheal, perivascular, and retropharyngeal spaces. It can lead to empyema, pericardial effusion, peritonitis, intrathoracic hemorrhage, and cardiac tamponade (2). Mortality due to DNM is reported at 25%–40% (1,3,4).

The overall success rate in these patients varies, depending on the timing of diagnosis and the

method(s) employed in their management. Due to the nonspecificity of symptoms and vagueness of the clinical presentation, patients may be admitted to various departments, including emergency, ear-nose-throat diseases, thoracic surgery, and dentistry. The lack of guidelines in the management of DNM necessitates vigilance on the part of healthcare professionals for timely and accurate referral of these patients.

We report our experience with 13 patients with DNM and discuss the surgical management of this highly fatal infectious condition, along with a review of the literature.

Received: 29.03.2012 – Accepted: 02.05.2012

¹ Department of Thoracic Surgery, Faculty of Medicine, Uludağ University, Bursa – TURKEY

² Department of Ear, Nose, and Throat, Faculty of Medicine, Karadeniz Technical University, Trabzon – TURKEY

³ Department of Thoracic Surgery, Faculty of Medicine, Karadeniz Technical University, Trabzon – TURKEY

Correspondence: Mehmet Muharrem EROL, Department of Thoracic Surgery, Faculty of Medicine, Uludağ University, Bursa – TURKEY

E-mail: muharremrol@hotmail.com

Materials and methods

Thirteen cases of DNM were treated between 2001 and 2012 in 2 tertiary care centers; 10 patients were male and 3 were female with ages ranging from 16 to 72 years. Various demographic and clinical characteristics and treatment interventions are summarized in the Table.

Computed tomography (CT) was performed in all suspected cases of DNM, and diagnoses were made on the basis of the CT findings and clinical observation. CT was performed postoperatively

for following up with patients. Typical findings on CT scans leading to a diagnosis of DNM include mediastinal collection with air bubbles and pleural effusion (Figures 1 and 2, case 8; Figure 3, case 13).

Results

Detailed data regarding patients' age, sex, primary cause of admission, time of onset before admission, surgical approach, mean hospitalization time, and final outcome are presented in the Table.

Table. Descriptive parameters of patients with DNM.

| Age | Sex | Coexisting pathology | Admission time after onset of symptoms (days) | Surgical intervention | Duration of hospitalization (days) | Fate | |
|-----|-----|----------------------|---|-----------------------|--|------|---|
| 1 | 16 | F | Odontogenic abscess | 10 | Tube thoracostomy-thoracotomy-cervical drainage | 9 | Exitus |
| 2 | 42 | M | Odontogenic abscess | 20 | Cervical drainage + tube thoracostomy + intrapleural streptokinase | 27 | Surviving |
| 3 | 51 | M | Tracheoesophageal fistula (laryngeal cancer) | 5 | Thoracotomy + cervical drainage | 30 | Exitus |
| 4 | 55 | M | Peritonsillar abscess | 7 | Thoracotomy + cervical drainage | 1 | Exitus |
| 5 | 50 | M | Peritonsillar abscess | 10 | Tube thoracostomy-thoracotomy | 22 | Exitus due to other reason (peptic ulcer perforation) |
| 6 | 26 | M | Odontogenic abscess | 7 | Tube thoracostomy-thoracotomy | 31 | Surviving |
| 7 | 32 | F | Odontogenic abscess | 7 | Mediastinal drainage (with cervical approach) | 11 | Surviving |
| 8 | 41 | M | Odontogenic abscess | 5 | Tube thoracostomy-thoracotomy-cervical drainage | 17 | Surviving |
| 9 | 38 | M | Esophageal foreign body | 7 | Median sternotomy (tracheoinnominate fistula) | 0 | Exitus |
| 10 | 42 | M | Peritonsillar abscess | 4 | Cervical drainage + bilateral thoracotomy | 35 | Surviving |
| 11 | 57 | F | Esophageal stenosis | 1 | Thoracotomy | 5 | Surviving |
| 12 | 72 | M | Laryngeal cancer + esophageal stenosis | 2 | Thoracotomy | 15 | Surviving |
| 13 | 52 | M | Esophageal perforation | 2 | Right thoracotomy + left tube thoracostomy | 16 | Surviving |

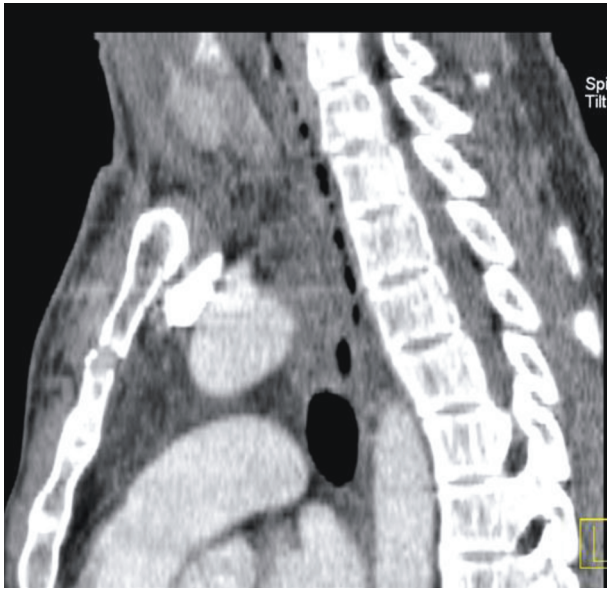


Figure 1. Thoracic CT scan demonstrating mediastinal collection with air bubbles (case 8).

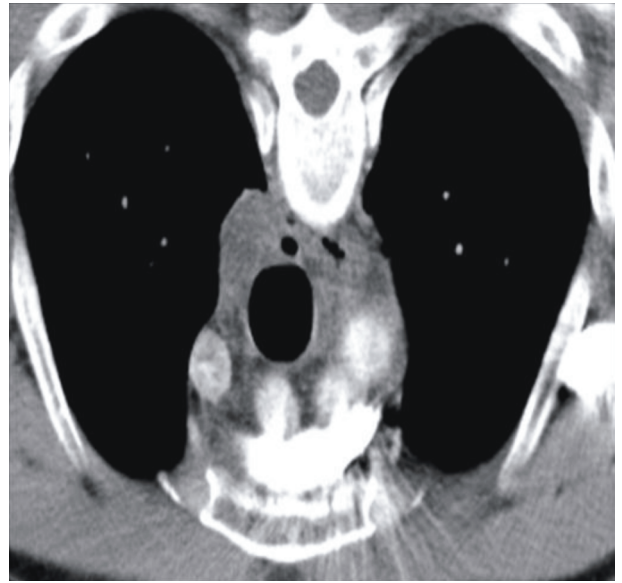

Figure 2. Thoracic CT scan demonstrating mediastinal collection of fluid and air (case 8).

There was a broad age range (16–72 years) among our patients, the male sex was more common, and infections of oropharyngeal origin were the leading cause. The second most common cause was esophageal perforation. Nine of the patients (69%) were admitted to the emergency clinic. Surgical interventions varied, depending on the presentation of DNM (Table). Intravenous broad-spectrum, effective antibiotic therapy was administered to all patients. Antibiotherapy should be effective to gram-positive, gram-negative, aerobic, and anaerobic agents.

In terms of complications and mortal cases, pharyngostomal fistula appeared as a complication on the fourth postoperative day in one case. This was treated successfully with a sternocleidomastoid muscle flap. Only one patient needed streptokinase therapy due to adhesions.

Three patients died for reasons beyond our control. One (case 9) was a prison inmate who had been misdiagnosed with tuberculosis. Antitubercular drugs had been administered in prison. He underwent emergency surgery via sternotomy because of massive hemoptysis, but died perioperatively. The second (case 3) had trachea esophageal fistula (TEF) and was operated on due to laryngeal cancer. His DNM diagnosis was delayed because the first symptoms had been obscured by the TEF. This was also a patient

with low immune resistance. The last patient (case 5) died as a result of peptic ulcer perforation.

Maximum hospitalization duration was 35 days (mean: 16.8 days). Eight of the 13 patients survived after intervention (a mortality rate of 38%).

Discussion

DNM is a form of acute suppurative mediastinitis that develops secondary to dental abscesses, peritonsillar abscesses, tonsillitis, and esophageal perforations.

Oropharyngeal infections spread to the mediastinum as a result of gravity, breathing, and negative intrathoracic pressure. The most common anatomic pathway is the lateral pharyngeal space through the retrovisceral space, inferiorly into the mediastinum (5). Administration of NSAIDs may also cause DNM. The mechanisms involved remain unknown (1,3,6).

Diagnosis was established on the basis of the DNM criteria described by Estrera et al. (7): 1) clinically evident oropharyngeal infection; 2) typical radiological mediastinitis findings; 3) evident necrotizing mediastinal infection at surgery or postmortem examination or both; and 4) an evident relationship between oropharyngeal or cervical infection and necrotizing mediastinal process.

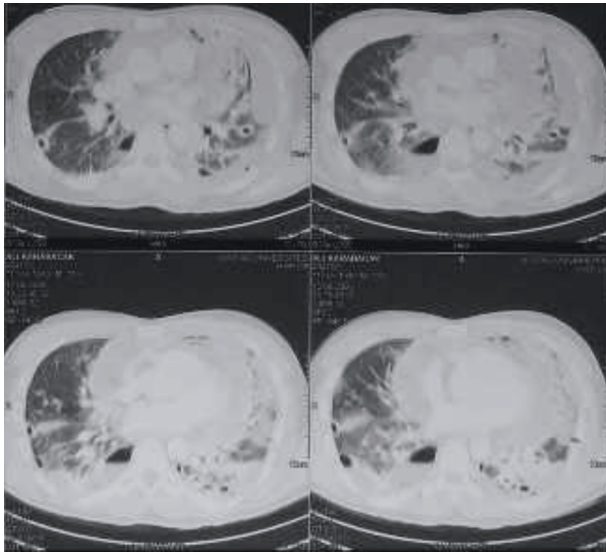


Figure 3. Thoracic CT scans demonstrating mediastinal collection of fluid and air (case 13).

Spread into the mediastinum may take 12–48 h (7). Odontogenic infections are the most common oropharyngeal infections reported as causes of DNM. Oropharyngeal infections were also the leading cause in our series. The origin lay in odontogenic and dental abscesses in 8 cases. DNM is a polymicrobial process in which anaerobic organisms predominate (7). *Mycobacterium tuberculosis* may also rarely be involved in DNM (8). Delayed diagnosis contributes significantly to the high mortality of DNM. The DNM diagnosis criteria defined by Estrera et al. (7) help with accurate and timely diagnosis. Diagnosis of DNM in our cases was confirmed on the basis of these criteria.

Conventional chest roentgenograms usually reveal only widening of the mediastinum, mediastinal emphysema, and pleural effusion, which are not specific for DNM. However, cervicothoracic CT findings such as signs of soft tissue infiltration with loss of normal fat mass or collection of fluid density in the absence or presence of air bubbles may indicate DNM. CT is also useful in the postoperative follow-up of patients with DNM. It can reveal persistent abscesses and/or undrained formations that should be drained either surgically or percutaneously under radiological guidance.

Different surgical approaches for transthoracic drainage and debridement applications for patients

with DNM have been reported in the literature. The choice of surgical technique depends on individual assessment of each patient. Transcervical mediastinal drainage used to be the most common approach before 1990. This technique does not always permit sufficient prompt drainage of the mediastinum (8).

Estrera et al. (7) recommended mediastinal drainage using a transthoracic approach for mediastinitis spreading below the tracheal bifurcation anteriorly or the fourth thoracic vertebrae posteriorly. They strongly recommended tracheotomy for providing a safe airway, which might otherwise be at risk due to massive edema and inflammation (7–10).

In a relatively large case series study consisting of 12 patients with a mortality rate of 16%, Marty-Ané et al. (2) recommended a transthoracic approach for adequate drainage and debridement. They also recommended aggressive surgery in order to establish a low mortality rate and they performed transcervical mediastinal drainage in only one patient.

Corsten et al. (11) reported that limited surgical interventions such as a subxiphoid approach or anterior mediastinotomy were generally insufficient in controlling DNM in terms of outcomes in their series of 8 patients. Their mortality rate was 12.5% (1/8). They reported that combined thoracic and cervical drainage yielded significantly better results than cervical drainage alone ($P < 0.05$).

The clamshell approach was advocated by Ris et al. (12) for effective drainage and debridement. Median sternotomy is unfavorable since not only may it lead to sternal dehiscence and osteomyelitis, but access to the posterior mediastinum is also unfeasible (13,14).

Endo et al. (15) classified DNM according to the degree of diffusion of DNM based on CT sections. Accordingly, Type I is localized in the upper mediastinum above the tracheal bifurcation and may not always require aggressive mediastinal drainage. Type IIA extends to the lower anterior mediastinum. Type IIB extends to the anterior and lower posterior mediastinum and demands complete mediastinal drainage with debridement by thoracotomy. They suggested that subxiphoidal mediastinal drainage or thoracoscopic operation without sternotomy may provide adequate drainage in type IIA. These recommendations are very important as they represent a minimally invasive approach.

We performed video-assisted mediastinoscopy for drainage of the superior mediastinum in one patient. This approach is a useful technique for DNM localized in the superior mediastinum (16,17).

Debridement of the mediastinum and thoracic cavities with early and radical surgery are very important for DNM.

Therefore, the first attempt to extend the life of the patient should be radical surgery. Repeated thoracoscopic surgical debridement and CT-guided procedures can be added to the first operation.

The deaths in the present study show the importance of early diagnosis in DNM. Medical treatment involving intravenous broad-spectrum antibiotic therapy alone is not sufficient; successful treatment requires surgical interventions such as drainage of the cervical and mediastinal collections, debridement and excision of the necrotic tissue, and mediastinal pleural irrigation. Antibiotherapy should be effective to gram-negative, gram-positive, aerobic, and anaerobic agents. Two of our patients died as a result of sepsis.

If necessary, these patients must be closely monitored in the intensive care unit. Broad-spectrum antibiotics must be started on the basis of the culture results (18).

CT scanning is important in imaging of patients with DNM at postoperative follow-up (19). There is a risk of fatality due to multiple organ failure or sepsis unless adequate drainage and meticulous debridement are performed.

Emergency physicians should also be very careful with these patients. Patients' medical histories are very important in the diagnosis of DNM. After diagnosis, broad-spectrum antibiotic therapy should be initiated immediately and surgical intervention should be planned.

DNM is a life-threatening condition that must be handled in a multidisciplinary and intensive manner. A combined cervical and thoracic surgical approach provides better results and lower mortality rates compared to the use of one of these options alone. Early surgical intervention is mandatory in the management of DNM. Even though thoracoscopy or tube thoracostomy may also be employed, cervical drainage together with thoracotomy provides satisfactory outcomes.

If necessary, repeated surgical procedures should be performed. Early diagnosis and radical surgical intervention for satisfactory outcomes are mandatory in the management of DNM.

References

- Freeman RK, Vallières E, Verrier ED, Karmy-Jones R, Wood DE. Descending necrotizing mediastinitis: an analysis of the effects of serial surgical debridement on patient mortality. *J Thorac Cardiovasc Surg* 2000; 119: 260–7.
- Marty-Ané CH, Berthet JP, Alric P, Pegis JD, Rouvière P, Mary H. Management of descending necrotizing mediastinitis: an aggressive treatment for an aggressive disease. *Ann Thorac Surg* 1999; 68: 212–7.
- Papalia E, Rena O, Oliaro A, Cavallo A, Giobbe R, Casadio C et al. Descending necrotizing mediastinitis: surgical management. *Eur J Cardio Thorac Surg* 2001; 20: 739–42.
- Chow AW, Roser SM, Brady FA. Orofacial odontogenic infections. *Ann Intern Med* 1978; 88: 392–402.
- Moncada R, Warphea R, Pickelman J. Mediastinitis from odontogenic infection and deep cervical infection. *Chest* 1978; 73: 497–500.
- Karkas A, Chahine K, Schmerber S, Brichon PY, Righini CA. Optimal treatment of cervical necrotizing fasciitis associated with descending necrotizing mediastinitis. *Br J Surg* 2010; 97: 609–15.
- Estrera AS, Landay MJ, Grisham JM, Sinn DP, Platt MR. Descending necrotizing mediastinitis. *Surg Gynecol Obstet* 1983; 157: 545–52.
- Steiner M, Grau MJ, Wilson DL, Snow NJ. Odontogenic infection leading to cervical emphysema and fatal mediastinitis. *J Oral Maxillofac Surg* 1985; 97: 88–92.
- Wheatley MJ, Stirling MC, Kirsh MM, Gago O, Orringer MB. Descending necrotizing mediastinitis: transcervical drainage is not enough. *Ann Thorac Surg* 1990; 49: 780–4.
- Bilgin G, Yılmaz AS, Köksal E, Gülhan E, Akbulut S, Ergul G et al. Desendan nekrotizan mediastinit: olgu sunumu. *Solumum Hastalıkları* 2002; 13: 218–20.
- Corsten MJ, Shamji FM, Odell PF, Frederico JA, Laframboise GG, Reid KR et al. Optimal treatment of descending necrotizing mediastinitis. *Thorax* 1997; 52: 702–8.
- Ris HB, Banic A, Furrer M, Caversaccio M, Cerny A, Zbären P. Descending necrotizing mediastinitis: surgical treatment via clamshell approach. *Ann Thorac Surg* 1996; 62: 1650–4.

13. Özyazıcıoğlu A, Ateş A, Ceviz M, Karapolat S, Bozkurt E, Koçak H. Penetrating cardiac injuries. *Turk J Med Sci*, 2002; 32: 499–503.
14. Özpolat B, Büyükaşık O, Osmanoğlu CG, Doğan S, Kargıcı H. Is cervicotomy enough for removal of retrosternal goiters? *Turk J Med Sci* 2008; 38: 561–5.
15. Endo S, Murayama F, Hasegawa T, Yamamoto S, Yamaguchi T, Sohara Y et al. Guideline of surgical management based on diffusion of descending necrotizing mediastinitis. *Jpn J Thorac Cardiovasc Surg* 1999; 47: 14–9.
16. Singhal P, Kejrival N, Lin Z, Tsutsui R, Ullal R. Optimal surgical management of descending necrotising mediastinitis: our experience and review of the literature. *Heart Lung Circ* 2008; 17: 124–8.
17. Shimizu K, Otani Y, Nakano T, Takayasu Y, Yasuoka Y, Morishita Y. Successful video-assisted mediastinoscopic drainage of descending necrotizing mediastinitis. *Ann Thorac Surg* 2006; 81: 2279–81.
18. Özkurt Z, Altıparlak Ü, İba Yılmaz S, Erol S, Özden K, Akçay MN. Reducing hospital infection rates in the burn unit by adherence to infection control measures: a six-year experience. *Turk Med J Sci* 2012; 42: 17–24.
19. Durmaz T, Metin MR, Keleş T, Ayhan H, Bozkurt E. A case with type IV dual left anterior descending coronary artery detected by multidetector computed tomography. *Turk J Med Sci* 2012; 42: 173–6.