

## CASE REPORT

### Congenital Facial Paralysis: Facial Nerve Hypoplasia

O. Afsin Ozmen, Burce Ozgen, Suay Ozmen, Levent Sennaroglu

Uludağ University Faculty of Medicine, Department of Otolaryngology Head and Neck Surgery – Bursa – Turkey, (OO)

Hacettepe University Faculty of Medicine Department of Radiology – Ankara – Turkey (BO)

Bursa Dörtçelik Childrens Hospital, Otorhinolaryngology Head and Neck Surgery – Bursa –Turkey, (SO)

Hacettepe University Faculty of Medicine Department of Otolaryngology Head and Neck Surgery – Ankara – Turkey, (LS)

Facial paralysis in a newborn is called congenital facial paralysis (CFP). The major role of the physician is to differentiate the etiology of the facial paralysis whether it is traumatic or developmental. This can be achieved by history and physical examination in some cases, however diagnosis may remain uncertain despite all efforts. We herein report a case of CFP, having a normal computed tomography (CT) of the temporal bone whereas a severely hypoplastic facial nerve was seen on the magnetic resonance imaging (MRI) which helps to determine the congenital etiology.

Submitted : 23 October 2009

Revised : 05 March 2010

Accepted : 07 March 2010

#### Introduction

Facial paralysis in a newborn is called congenital facial paralysis. Two most common etiology of CFP are birth trauma and developmental [1]. Differentiation between birth trauma and developmental causes of CFP is the most important issue in planning the management and informing the parents about the prognosis. This can be achieved by history and physical examination in some cases, however diagnosis may remain uncertain despite all efforts. We herein report a case of CFP, having a normal computed tomography (CT) of the temporal bone whereas a severely hypoplastic facial nerve was seen on the magnetic resonance imaging (MRI) which helps to determine the congenital etiology.

#### Case Report

A 7-months-old boy was presented with left-sided facial paralysis noticed at birth. There was no history of birth trauma or facial paralysis in his family. He had facial paralysis affecting all divisions of facial nerve, however, function at the oral commissure improved partially afterwards. His face was symmetric at rest. He also had right clubfoot. Rest of the otolaryngologic and systemic examinations was normal. He was found to have normal hearing bilaterally with transient evoked otoacoustic emissions, which was confirmed later with pure tone audiometry. EMG revealed severe

axonal lesion on the left side, left orbicularis oris muscle was found to be innervated by the right facial nerve. Temporal bone and facial canal were found to be normal in the computed tomography (CT) (Figure 1). However magnetic resonance imaging (MRI) scans revealed a severely hypoplastic facial nerve at cisternal and cannalicular segments (Figure 2). No improvement in the facial functions was observed in 2 years of follow-up.

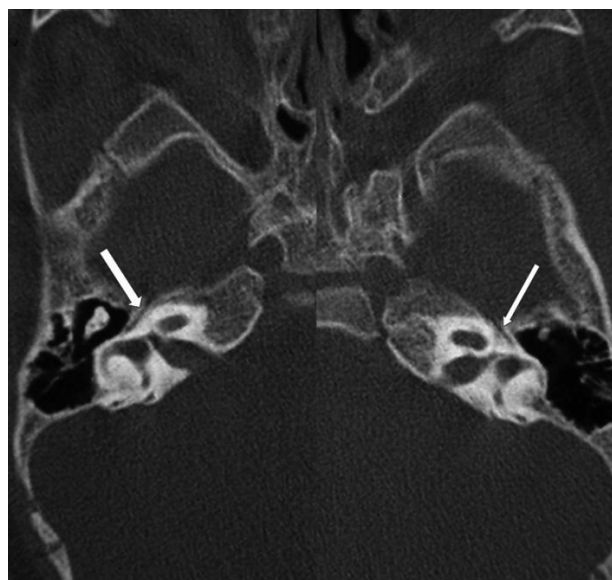


Figure 1. Normal facial canal in the computerized tomography

#### Corresponding address:

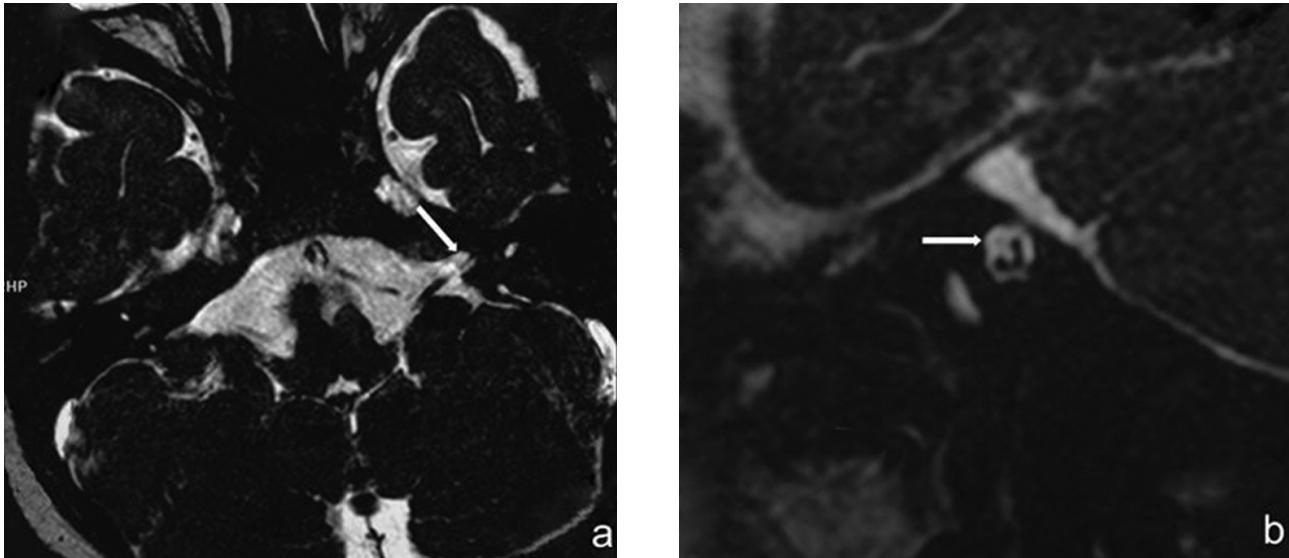
O. Afsin Ozmen

Uludağ Üniversitesi Tıp Fakültesi Kulak Burun Boğaz A.D.

16059 Görükle-Bursa-TÜRKİYE

Phone: +90 224 295 26 21; Mobile : +90 532 624 22 99; Fax: +90 224 442 80 91; E-Mail : oaozmen@yahoo.com

Copyright 2005 © The Mediterranean Society of Otolaryngology and Audiology



**Figure 2.** Severely hypoplastic facial nerve seen in the anterosuperior quadrant of the left internal auditory canal.

### Discussion

Congenital facial paralysis is an uncommon situation with an occurrence of 2 in 1,000 alive births. The major role of the physician is to differentiate the etiology of the facial paralysis whether is traumatic or developmental. This distinction is important not only for treatment options and prognosis but may have medicolegal implications as well [2]. Traumatic CFP may be diagnosed by the history and physical examination. Complicated delivery, prematurity, ecchymosis around ear, facial paralysis affecting mostly lower division are factors associated with traumatic CFP. Recovery even with synkinesis is the rule in traumatic cases.

Developmental CFP may be diagnosed more easily when it is part of a syndrome. CFP may be related to a number of syndromes such as Mobius syndrome, velocardiofacial syndrome, Goldenhar's syndrome and Poland's syndrome [3]. Otologic, craniofacial and systemic anomalies should be evaluated carefully in a patient born with facial paralysis. Bilateral involvement, other cranial neuropathies also imply developmental etiology. Predominance of upper or lower divisions may be seen. Facial tonus is usually good in these cases. However, when the CFP occurs as an isolated incident the diagnosis may be more challenging.

In our case isolated unilateral CFP in the child of a primiparous mother supports a traumatic cause of

CFP. On the other hand there was no finding such as ecchymosis, hemotympanum in physical examination. No recovery in facial nerve functions emphasizes developmental etiology. Late admission in this case lessens the value of the electrophysiologic tests. Although there were controversial findings in the EMGs, no sign of reinnervation is thought to be compatible with developmental origin.

Contralateral innervation of the facial nerve may be seen in normal people but, its incidence increases significantly after facial nerve injury [4]

Absence of facial canal may be recorded in CT scan despite a visible facial nerve in internal auditory canal (IAC) [5]. On the other hand facial nerve may be abnormal in spite of a normal CT as seen in the present case. Brainstem hypoplasia, abnormal facial nucleus, aplasia of the facial nerve may be seen in MRI with a normal or abnormal CT [6,7]. Internal auditory canal absence or stenosis may also be revealed in CT or MRI. Even in those cases, facial nerve function is intact in the majority of the cases, whereas vestibulocochlear remains dysfunctional [8].

The structure which is seen as severely hypoplastic facial nerve in the MRI may represent the fibrous cord found in the surgical explorations of the CFP [9].

Traumatic CFP has 90% chance of spontaneous recovery. Although being controversial, steroid treatment may be considered in a case diagnosed with traumatic CFP [10]. Surgical exploration may also be

indicated in cases with rapid deterioration. This good prognosis is not shared by developmental cases. Surgical exploration is discouraged in developmental cases because the facial nerve is absent or like a fibrous cord<sup>[9]</sup>. Nerve transpositions are useless in CFP cases leaving only regional or microneurovascular muscle transfers and static techniques as the treatment alternatives<sup>[11]</sup>.

This case shows the MRI examination has a crucial role in the evaluation of patients with CFP and should be present in the diagnostic battery of the CFP. CT findings may be normal whereas, a hypoplastic facial nerve on MRI may help us to attain definite diagnosis and direct the clinical management and inform the parents about the prognosis of the disease.

### **References**

1. Falco NA, Ericson E. Facial nerve palsy in the newborn: incidence and outcome. *Plast Reconstr Surg.* 1990; 85:1-4
2. May M. Facial paralysis at birth: medicolegal and clinical implications. *Am J Otol.* 1995; 16:711-2.
3. Orobelle P. Congenital and acquired facial nerve paralysis in children. *Otolaryngol Clin North Am* 1991; 24:647-52
4. Yang ZH, Cai ZG, Yu GY. A study of 108 cases on facial nerve contralateral innervations after facial nerve injury. *Zhonghua Kou Qiang Yi Xue Za Zhi* 2004; 39: 425-7.
5. Sano M, Kaga K, Takeuchi N, Kitazumi E, Kodama K. A case of Mobius syndrome--radiological and electrophysiological findings. *Int J Pediatr Otorhinolaryngol.* 2005; 69:1583-6.
6. Verzijl HT, Valk J, de Vries R, Padberg GW. Radiologic evidence for absence of the facial nerve in Mobius syndrome. *Neurology.* 2005; 8;64:849-55.
7. Jemec B, Grobbelaar AO, Harrison DH. The abnormal nucleus as a cause of congenital facial palsy. *Arch Dis Child.* 2000; 83:256-8.
8. Lin KM, Huang CC, Leung JH. Congenital unilateral facial palsy and internal auditory canal stenosis. *Pediatric Neurology* 2008; 39:116-119.
9. May M, Schaitkin BM, Shapiro AM. Facial nerve disorders in newborns and children. In May M, Schaitkin BM (eds.). *The Facial Nerve.* New York: Thieme, 2000: pp. 358
10. Evans AK, Licameli G, Brietzke S, Whittemore K, Kenna M. Pediatric facial nerve paralysis: patients, management and outcomes. *Int J Pediatr Otorhinolaryngol.* 2005; 69:1521-8.
11. Tate JR, Tollefson TT. Advances in facial reanimation. *Curr Opin Otolaryngol Head Neck Surg.* 2006; 14:242-8