

RESEARCH ARTICLE

J Res Vet Med. 2021; 40 (1) 31-34
DOI:10.30782/jrv.811350

The Effect of Gender Factor on Mandibular Morphometry in Abaza Goats

 Semine DALGA¹,  Kadir ASLAN¹

¹Department of Anatomy, Faculty of Veterinary Medicine, Kafkas University, Kars, Turkey

Received 15-10-2020 Accepted 08-07-2021

Abstract

In this study, the mandibles of Abaza goats were examined macroanatomically and morphometrically. A total of 14 adult (7 female / 7 male) Abaza goat mandibles of both sexes of different age and of body weight were used. Mandibles were removed from the head and cleaned of skin and rough meat, then macerated with hydrogen peroxide for 25-30 minutes and the lengths of 16 different points were measured by electronic caliper (0.00, BTS, UK) according to the literature. Mean, standard deviation and correlation values of all measurements were determined in SPSS (20.0) version program. As a result of the statistics, the mean length of mandible in females was 158,73 mm and in males 148,72 mm. The mean height was 90.46 mm in females and 88.60 mm in males. Morphometric measurements showed that all lengths except L15 were higher in female Abaza goats. Only a significant difference was found between mandibular height (L16) at the level of the anterior alveolar edge of the second premolar tooth ($P < 0,01$).

Keywords: Abaza goat, Mandible, Morphometry

Introduction

Abaza goats are generally bronze, white, black and brown. Mouth, around the eyes, horns and legs may be black. The bucks have sword-shaped, flat and broad shaped horns, while the females can be horned or hornless. The hairs are short, thin and soft as silk. It has been reported that meat and milk yields are superior to other domestic goat breeds, especially in the region.¹

Morphometry is a research method that allows numerical or graphical statistical analysis of width, length or angle measurements between certain two points.² Morphometric analysis is a frequently preferred method for revealing the differences between the sexes, osteological evaluations in the same animal species or between different animal species, in determining the models of endangered or extinct

organisms and in revealing the differences in shape due to environmental and internal factors.³⁻⁴ Nutrition, stress, race, sex hormones, growth factor, temporomandibular joint, environmental and genetic factors affect the development of mandible.²⁻⁸ Due to the large number of factors affecting the development of mandible in the literature have been reported different methods of morphometric studies on various animal species mandibles.⁹⁻¹³

Although there are some studies on Abaza goats,¹⁴⁻¹⁵ no studies on mandible morphometry have been found. This study was carried out to improve the knowledge about goat anatomy in the literature.

Materials and Methods

A total of 14 adult Abaza goat mandibles of both sexes of different age (2-3) and of body weight (females mean 45-55

* Corresponding author: Department of Anatomy, Faculty of Veterinary Medicine, Kafkas University, Kars, Turkey

kg, males 60-75 kg.) were used. The necessary permissions were obtained from the Kafkas University local ethical committee (KAÜ-HADYEK/2020-146). Mandibles were obtained during the slaughter of the Abaza goats from the established at Kafkas University Veterinary Faculty Training Research and Application Farm. After removing the mandibles from the head, the mandibles were boiled in a controlled way to remove the soft tissues. Then, the bones were cleaned with hydrogen peroxide for 25-30 minutes. After these processes, the lengths from 16 different points were measured by using electronic caliper (0.00, BTS, UK) in accordance with the literature information¹⁶ (Figure 1). The mandibles were photographed with a digital camera (Canon Digital Camera Zoom Lens), the mean, standard deviation and correlation values of all measurements were determined in the SPSS (20.0) package program. The determined values are indicated in Table 1 and Table 2. The nomenclature in this research was based on the terms of Von Den Driesch.¹⁶

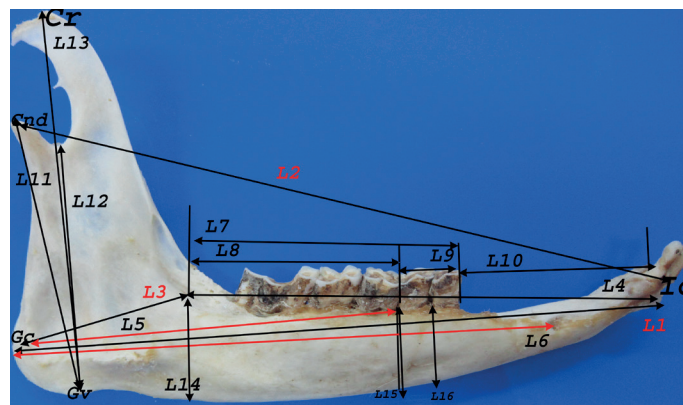


Figure 1: The length measurements of the mandible

Table 1: Mean and standard deviation values of mandibular measurements in Abaza goats (mm)

Parameter	Female (mean- std.deviation mm.)	Male (mean-std.deviation mm.)
L1	158,73± 23,27	148,72± 2,03
L2	163,81± 22,61	153,46± 2,54
L3	43,87 ±7,32	40,12 ±1,04
L4	123,51±17,77	115,59±2,29
L5	104,57±16,18	98,25±2,49
L6	128,87±18,86	118,84±2,38
L7	74,04±13,63	68,88±2,74
L8	58,28±12,21	53,66±2,45
L9	16,15±1,87	15,56±0,73
L10	34,07±4,96	37,38±1,34
L11	63,57±9,60	63,33±2,04
L12	58,76±8,87	57,07±1,77
L13	90,46±13,44	88,60±2,72
L14	36,75±6,35	35,61±1,61
L15	21,98±3,56	23,52±0,98
L16	18,34±1,21	21,46±0,91

Condylion (cnd); the caudal endpoint of processus condylaris, Cr (coronion); the caudal endpoint of processus coronoideus, Gonionventrale (Gv); The inferior endpoint of the angular mandible, Gonioncaudale (Gc); The caudal endpoint of processus angularis, Infradentale (Id); The rostro-superior point of the alveoli between incisive teeth16.

- Length 1(L1): lenght between gonion caudale and infradentale.
- Length 2(L2): length between infradentale and aboral edge of condylar process.
- Length 3(L3): length between gonion caudale and aboral alveolar edge of 3rd molar tooth.
- Length 4(L4): length between infradentale and aboral alveolar edge of 3rd molar tooth.
- Length 5(L5): length between gonion caudale and rostral alveolar edge of 2nd premolar tooth.
- Length 6(L6): length between gonion caudale and aboral edge of mental foramen.
- Length 7(L7): length between first premolar tooth and last molar tooth.
- Length 8(L8): length between first and last molar teeth.
- Length 9(L9): length between first and last premolar teeth.
- Length 10(L10): length of diastema.
- Length 11(L11): length between gonion ventrale and cnd
- Length 12(L12): length between gonion ventrale and the deepest point of incisura mandibulae
- Length 13(L13): length between gonion ventrale and coronion.
- Length 14(L14): height of mandible level of alveolar edge of 3rd molar tooth.
- Length 15(L15): height of mandible level of rostral alveolar edge of 1st molar tooth.
- Length 16(L16): height of mandible level of rostral alveolar edge of 2nd premolar tooth.

Table 2: Correlation analysis of mandible values in Abaza goats

↘Female	L1	L2	L3	L4	L5	L6	L7	L8	L9	L10	L11	L12	L13	L14	L15	L16
L1		.891*	.348	.672*	.736*	.815**	.863**	.687*	.308	.328	.860**	.515	.553	.124	.561	.388
L2	.988**		-.013	.479	.549	.706**	.625	.559	-.068	.294	.521	-.077	-.112	-.450	.420	.439
L3	.952**	.963**		.567	.655*	.301	.510	.384	.715*	.027	.634*	.674*	.743*	.327	.146	-.075
L4	.967**	.939**	.855**		.846**	.679*	.673**	.882**	.458	-.008	.882**	.653*	.607	.066	.810**	.577
L5	.984**	.966**	.896**	.993**		.699*	.806**	.715*	.248	.181	.884**	.495	.535	-.029	.581	.428
L6	.995**	.989**	.970**	.949*	.972**		.500	.527	.203	.652*	.869**	.398	.347	-.020	.398	.164
L7	.985**	.970**	.916**	.982**	.993**	.981**		.845**	.441	-.273	.710**	.410	.439	-.163	.807**	.751**
L8	.986**	.968**	.933**	.976**	.985**	.982**	.995**		.480	-.276	.711**	.423	.454	-.166	.914**	.819**
L9	.785**	.814**	.889**	.638*	.670*	.799**	.602*	.734*		-.195	.454	.625	.673*	.311	.240	.052
L10	.909**	.930**	.874**	.856**	.887**	.904**	.872**	.871**	.754**		.370	.069	-.003	.087	-.342	-.558
L11	.974**	.993**	.979**	.906**	.944**	.981**	.954**	.956**	.837**	.914**		.709	.696*	.202	.571	.286
L12	.974**	.991**	.970**	.920**	.954**	.983**	.967**	.966**	.801**	.903**	.897**		.958**	.790**	.391	.042
L13	.983**	.989**	.983**	.925**	.955**	.992**	.969**	.974**	.830**	.883**	.993**	.993**		.730**	.397	.084
L14	.698*	.714*	.802**	.618	.651*	.739*	.731*	.757*	.654*	.539	.755*	.773**	.789**		-.092	-.345
L15	.644*	.686*	.804**	.480	.534	.696*	.612	.638*	.775**	.593	.725*	.717*	.734*	.883**		.881**
L16	.700*	.746*	.619	.735*	.746*	.699*	.704*	.668*	.478	.694*	.723*	.739*	.695*	.290	.239	

Results

In this study, the mean and standard deviation values of the measurements of Abaza goats are given in Table 1. The results of the correlation analysis are given in Table 2 and some of the previous studies in the literature are given in Table 3.

Tablo 3: Mandible values of some sheep and goat breeds

Parameters	Hemşin sheep	Morkaraman sheep	Tuj sheep	Mehra- Ban sheep	WAD goat	Black bengal goat	Female abaza goat	Male abaza goat
.1	16.78	15.24	14.78	15.76	12.00	14.21	15.87	14.87
.10	4.38	3.72	3.64	3.98	-	-	3.4	3.7
.11	6.85	6.21	6.09	7.75	2.68	6.38	6.35	6.33
.13	9.42	8.7	8.54	9.57	6.90	8.83	9.0	8.8

Discussion and Conclusion

In the literature, with respect to the mandibular length and height were 167.8 and 94.2 mm in Hemshin sheep¹⁸, 152.4 and 87.0 mm in Morkaraman sheep,¹⁹ and Tuj sheep 147.8 and 85.4 mm¹⁹, respectively. 157.6 and 95.7 mm in Mehra-ban sheep,²⁰ 181.6 and 107.9 mm in Barbados sheep,²¹ in Yankasa sheep,²² 198.0±0.28 and 129.0±0.57 were reported as 186.30±9.30 and 108.68±2.36 mm in Hasmer sheep,²³ in Awassi sheep²⁶ mandibular length 180.22±11.91 while Avdic et al²⁴., reported that it was 176.0 and 99.6 mm in a study on sheep in Sarajevo. In Abaza goats 158,73 mm and 90,46 mm in females 148,72 and 88,60 mm in males respectively. In the literature, it has been reported the mandibular height of the posterior alveolar edge of the 3rd molar tooth of Hasmer sheep²³ 37.47 ± 3.25 mm, from Hemshin sheep¹⁸ 37.93 mm and Morkaraman sheep¹⁹ 38.88 mm. In Abaza goats, it was found to be 36.75 mm in females and 35.61 mm in males. In the studies, it was reported that the length between Gv and Cnd was 68.52 in Hemshin sheep¹⁸ and 74.58 ± 1.75 mm in Hasmer sheep²³ 77.50 mm. This parameter was determined as 63.57 mm in female Abaza goats and 63.33 mm in male Abaza goats.

The length of the first and last molar teeth (L8) has been reported as 57.2 mm in Hemshin sheep¹⁸, in Hasmer sheep²³ 49.26 ± 3.11 mm, and 53.12 mm in Morkaraman sheep¹⁹. In our study, it was measured as 58.28 mm in females and 53.66 mm in males Abaza goats.

Diastema length was reported, in Hasmer sheep²³ 43.54 ± 3.48 mm, Hemshin sheep¹⁸ 43.74, in Awassi sheep²⁶ 46.27± 3.29 mm, for male and 48.97±5.82 for female, animals studied in the literature. In our study, this parameters were observed 37.38 mm in females, 34.07 in males.

The length between the caudal tip of the processus angularis and the aboral edge of the mental foramen was 137.4 mm in Mehraban sheep²⁰, 152.3 mm in Barbados sheep²¹ and 165.0 Yankasa sheep²², 112.9 in Iranian sheep²⁵, and 149.40 ± 11.02 in Hasmer sheep²³. This parameter was determined as 128.87 mm in female Abaza goats and 118.84 mm in male Abaza goats.

As a result; Abaza goat mandible was measured at 16 points and the obtained values were compared with other small

ruminant breeds. Morphometric measurements showed that all lengths except L15 were higher in female Abaza goats. According to the results of the correlation analysis, a strong positive correlation was observed between length L1-L2, L11-L2, L12-L2 and L13-L6 in female Abaza goats. In male Abaza goats, a significant positive correlation was observed between lengths L1-L6, L4-L5, and L4-L11. As a result of the statistical analysis, it was seen that the length of mandible in male and female Abaza goats was lower than that of Hemshin sheep but higher than other sheep and goat species in the table 3.

In this study, macroanatomical and morphometric features of Abaza goat mandible were determined in terms of gender. The findings obtained in the literature have added data to the literature for Abaza goats at extinction point, and have provided the recording of breed specific mandible data in the use of goats as animal models in medicine and dentistry studies.

References

1. Batu S. Türkiye Keçi Irkları. Ankara Üniversitesi Veteriner Fakültesi Yayınları, Ankara, 1951.
2. Rohlf FJ, Marcus LF. A revolution in morphometrics. *Trendsecol. Evol.*, 8, 129-132;1993.
3. Ketani AM, Sağsöz H. Sıçanlarda mandibular kondilin histolojik yapısı üzerine cinsiyetin etkilerinin histomorfometrik olarak incelenmesi. *Atatürk Üniv Vet Bil Derg.* 2009; 4: 31-38.
4. Çakır A, Yıldırım İG, Ekim O. Craniometric measurements and some anatomical characteristics of the cranium in Mediterranean Monk Seal (*Monachus monachus*, Hermann 1779). *Ankara Üniv Vet Fak Derg.* 2012; 59: 155-162.
5. Kiliaridis S, Thilander B, Kjellberg H, Topouzelis N, Zafiriadis A. Effect of low masticatory function on condylar growth: A morphometric study in the rat. *Am J Orthod Dentofacial Orthop* 1999; 116: 121-125.
6. Luca L, Roberto D, Francesca SM, Francesca P. Consistency of diet and its effects on mandibular morphogenesis in the young rat. *Prog Orthod.* 2003; 4: 3-7.
7. Weijs WA. Mandibular movements of the albino rat during feeding. *J Morphol.* 1975; 145: 107-124.
8. Fujita T. Effects of sex hormone disturbances on craniofacial growth in new born mice. *J Dent Res.* 2004; 83: 250-254.
9. Alpak H. Morphometry of the mandible of German Shepherd Dog (Alsatian) puppies using computed tomographic analysis. *Israel J Vet Med.* 2003; 58: 15-17.
10. Onar V, Kahvecioğlu O, Mutuş R, Alpak H. Alman kurt köpeklerinde mandibula'nın morfometrik analizi.

- Turk J Vet Anim Sci. 1999; 23: 329-334.
11. Yalçın H, Kayış SA, Arslan A. Ağaç, yer sincabı ve ratın mandibula'sı üzerinde karşılaştırmalı makro-anatomik, mekanik ve geometrik morfometrik çalışma. *Vet Bil Derg.* 2007; 23: 83-95.
 12. Yalçın H, Kaya MA, Arslan A. Comparative Geometrical Morphometries on the Mandibles of Anatolian Wild Sheep (*Ovis gmelini anatolica*) and Akkaraman Sheep (*Ovis aries*). *Kafkas Uni. Vet. Fak. Derg.* 2010; 16 (1) 55-61,.
 13. Özkan E, Jashari T, Gündemir O, Gezer İN. Morphometric analysis of the mandible of Bardhoka autochthonous sheep in Kosovo. *Anat Histol Embryol.* 2020;00:1-5. <https://doi.org/10.1111/ahe.12568>.
 14. Kuru M, Kuru B, Kulaksız R, Arı UÇ, Oral H. Abaza Keçilerinde Progesteron Destekli Östrus Senkronizasyonunun Bazı Reprodüktif Parametrelere Etkileri. *Kocatepe Vet J.* (2017);10 (3): 164 - 171 DOI: 10.5578/kvj.57526 .
 15. Dalga S. Topographic and morphometric study of the mental foramina of Abaza goats with its clinical implication for regional anesthesia [published online ahead of print, 2019 Nov 21]. *Folia Morphol (Warsz).* 2019;10.5603/FM.a2019.0122. doi:10.5603/FM.a2019.0122
 16. Von den driesch, A.. A guideto the measurement of animal bones from archaeological sites. 1976;Pp. 31-34. Peabody Museum Bulletin I. Cambridge M.A., Harvard University.
 17. *Nomina Anatomica Veterinaria*, 2017: International committee on veterinary gross anatomical nomenclature (6th ed. (Revised version)). Published by the Editorial Committee Hannover (Germany), Columbia, MO (USA), Ghent (Belgium), Sapporo (Japan).
 18. Dalga S, Aslan K, Kırbaş G. Hemşin Koyunu mandibulası üzerinde morfometrik bir çalışma. *Atatürk Üniv Vet Bil Derg.* 2017; 12(1): 22-7.
 19. Demiraslan Y, Gülbaz F, Özcan S, Dayan MO, Akbulut Y. Morphometric analysis of the mandible of Tuj and Morkaraman sheep. *J Vet Anat.* 2014; 7: 75-86.
 20. Karimi I, Onar V, Pazvant G, Hadipour MM, Mazaheri Y. The cranial morphometric and morphologic characteristics of Mehraban sheep in Western Iran. *Global Veterinaria.* 2011; 6 (2): 111-7.
 21. Mohamed R, Driscoll M, Mootoo N. Clinical anatomy of the skull of the Barbados Black Belly sheep in Trinidad. *Int J Curr Res Med Sci.* 2016; 2 (8): 8-19.
 22. Shehu SA, Bello A, Sonfada ML, Suleiman HM, Umar AA, Danmaigoro A, Garba S, Abdullahi AU. Morphometrical study of the mandibular bone of female Yankasa sheep. *International Journal of Current Science and Multidisciplinary Journal.* 2019; 2(1): 1-10
 23. Özüdoğru Z, İlgin R, Özdemir D. Hasmer koyunu mandibula'sı üzerinde makroanatomik ve morfometrik incelemeler. *Erciyes Üniv Vet Fak Derg.* 2019; 16(3): 218-223.
 24. Avdic R, Hadziomerovic N, Tandir F, Pamela B, Velida C. Analysis of morphometric parameters of the Roe deer mandible (*Capreolus capreolus*) and mandible of the sheep (*Ovis aries*). *Veterinaria.* 2013; 62: 1-9.
 25. Monfared AL. Clinical anatomy of the skull of Iranian native sheep. *Global Veterinaria.* 2013; 10 (13): 271-5.
 26. Yılmaz B. İvesi Koyunlarında (*Ovis aries*) Mandibula'nın Morfometrik İncelemesi. *Harran Üniv Vet Fak Derg,* 2020; 9 (2): 189-193.