

# Minimally invasive plate osteosynthesis for short oblique diaphyseal tibia fractures: does fracture site affect the outcomes?

Journal of International Medical Research

48(10) 1–8

© The Author(s) 2020

Article reuse guidelines:

[sagepub.com/journals-permissions](https://sagepub.com/journals-permissions)

DOI: 10.1177/0300060520965402

[journals.sagepub.com/home/imr](https://journals.sagepub.com/home/imr)

Gokay Eken<sup>1</sup> , Cenk Ermutlu<sup>2</sup>,  
Kemal Durak<sup>2</sup>, Teoman Atici<sup>2</sup> ,  
Bartu Sarisozen<sup>2</sup> and Adnan Cakar<sup>2</sup>

## Abstract

**Objective:** To report the results of patients with short oblique diaphyseal tibia fractures treated with minimally invasive plate osteosynthesis (MIPO). The secondary aim was to understand the effect of fracture location (midshaft or distal 1/3) on outcomes.

**Methods:** Twenty-eight patients with short oblique ( $>30^\circ$ ) tibial shaft fractures (AO/OTA 42A2) treated with plate and MIPO technique between 2015 and 2019 were retrospectively assessed. Age, gender, follow-up time, fracture type (open or closed), operation time, postoperative infection rate, union time, ankle joint range of motion, and complications were analyzed. Patients' radiographs at a minimum 1-year follow-up were evaluated for malunion, nonunion, and implant-related complications.

**Results:** Mean age and follow-up time were  $47.0 \pm 15.7$  years and  $18.3 \pm 12.1$  months, respectively. Mean bone union time was  $3.66 \pm 1.04$  months in middle 1/3 diaphysis and  $4.23 \pm 1.48$  months in distal 1/3 tibia fractures. Seven (25%) patients developed superficial infections. Mean union time, malunion rate, coronal and sagittal angulation, operation length, and infection rate were similar between the groups.

**Conclusion:** MIPO is an effective method for treatment of short oblique diaphyseal tibia fractures, and results in few complications. Both distal and midshaft fractures have similar union and malunion rates.

<sup>1</sup>Bursa Acibadem Hospital, Orthopedics and Traumatology Department, Nilufer Bursa, Turkey

<sup>2</sup>Uludag University Faculty of Medicine, Orthopedics and Traumatology Department, Nilufer Bursa, Turkey

## Corresponding author:

Gokay Eken, Bursa Acibadem Hospital, Orthopedics and Traumatology Department, FSM Bulvarı, Sumer sokak No: 1 Nilufer Bursa 16110, Turkey.

Email: [gokay\\_eken@yahoo.com](mailto:gokay_eken@yahoo.com)



## Keywords

Tibia fracture, minimally invasive percutaneous osteosynthesis, plate osteosynthesis, bone union, nonunion, malunion

Date received: 17 July 2020; accepted: 18 September 2020

## Introduction

Tibial shaft fractures are the most commonly occurring long bone fractures, with a reported incidence of 16.9/100,000 per year.<sup>1</sup> These fractures can be treated conservatively, or operatively with intramedullary nailing (IMN), plate osteosynthesis, or external fixation depending on the fracture pattern and soft tissues.<sup>2,3</sup> Although improvements have been made in intramedullary nails, locking plates, and minimally invasive plate osteosynthesis (MIPO) techniques, no consensus has been achieved on the optimal surgical technique.<sup>4,5</sup> IMN has become popular for the treatment of displaced diaphyseal tibia fractures, especially transverse fractures.<sup>6</sup> Following IMN, a 71% incidence of chronic anterior knee pain was reported, and malalignment can occur following IMN of distal diaphyseal tibial fractures.<sup>7</sup>

Using a plate with the MIPO technique remains a viable option, especially in comminuted, segmental, distal, or proximal fractures, and in cases with short oblique midshaft fractures.<sup>3</sup> MIPO follows the principle of bridge plate osteosynthesis, resulting in relative stability.<sup>8</sup> Placing the plate through a minimally invasive approach is desirable because it requires less soft tissue dissection, permits biological fixation, and promotes union. Despite these advantages, its use in fractures of the tibial diaphysis is largely limited to comminuted or segmental fracture patterns because of the increased popularity of IMN. Inability to achieve absolute stability by using interfragmentary lag screws or delayed weight bearing are

potential risks of their use in midshaft fractures.

It is generally taught that metaphyseal fractures heal differently than diaphyseal fractures.<sup>9</sup> A larger active bone surface, a better blood supply, and a thicker periosteum containing more cells are possible reasons for better healing in the metaphyseal region.<sup>10</sup> To our knowledge, no clinical studies have compared the outcomes of diaphyseal fractures in different regions. Our hypothesis was that the distal third of the tibial shaft is more similar to the metaphyseal region, with better blood circulation and healing compared with the middle third.

The primary aim of this study was to report the results of patients with short oblique diaphyseal tibia fractures treated with a MIPO approach. The secondary aim was to understand the effect of fracture location (midshaft or distal 1/3) on outcomes.

## Materials and methods

After institutional ethics/review board approval (Uludag University Faculty of Medicine Ethics Board/Bursa-Turkey, date and number: 13/05/2020 – 2020 8/35), we included patients with short oblique (>30°) tibial shaft fractures (AO/OTA 42A2) treated with a limited contact - dynamic compression plate (Synthes®, West Chester, PA, USA) and MIPO technique between February 2015 and December 2019. All data were collected retrospectively. Patients were divided into two groups according their fracture site in the

tibia. Group 1 consisted of patients with middle 1/3 diaphyseal fractures and group 2 consisted of patients with distal 1/3 diaphyseal fractures. We de-identified all patient details.

Inclusion criteria for this study were age >18 years old, patients with middle 1/3 and distal 1/3 closed tibial fractures who underwent plate and screw fixation with a MIPO technique, and a minimum follow-up of 12 months.

Excluded criteria included patients who could not be operated on within the acute period (7–10 days), fractures with neurovascular injury, presence of an additional fracture of the tibia, pathologic fractures, patient under 18 years old, previous tibia surgery on the affected side such as deformity surgery, a follow-up period less than 12 months, and ipsilateral neurological deficit.

Age, gender, follow-up time, fracture type (open or closed), operation time, postoperative infection rate, union time, ankle joint range of motion, and complications were analyzed. Patients' radiographs at the minimum 1-year follow-up were evaluated for malunion, nonunion, and implant-related complications. Bone union was defined as the presence of both clinical and radiologic union findings, including the ability to bear full weight without support on the injured leg with no fracture site pain or tenderness, if other injuries allowed, together with the presence of mature bridging callus in at least three of four cortices on anteroposterior and lateral radiographs.<sup>11,12</sup> Malunion was assessed radiologically and defined as angular deformity greater than 4°, translation or shortening greater than 5 mm, or rotational malalignment greater than or equal to 10°.<sup>13</sup>

### *Surgical technique*

After obtaining informed consent from all patients, operations were performed. Distal tibia long anatomical LC-DCP with

3.5-mm screws were used for the distal metaphysis and 4.5-mm non-locking and 5-mm locking screws (Synthes®, West Chester, PA, USA) were used for the diaphyseal segment. In accordance with the MIPO technique the plate was placed through a small medial incision on the medial side of the distal tibia and advanced distal to proximal without opening the fracture site. Compression was achieved by placing a cortical non-locking screw eccentrically in the oval holes in either the proximal or distal fracture segment, depending on fracture location and geometry. An anatomic reduction was not attempted or achieved. Relative stability was obtained with correction of the length and alignment for secondary bone healing. The fracture site was not opened in any of the cases. No interfragmentary lag screws were used. According to AO and MIPO principles, we reached maximum plate/screw density of 0.6. We applied the plates with a plate length/fracture length ratio ranging from 8 to 10. Plaster or fiberglass were not applied and patients were permitted full knee and ankle motion on the first postoperative day. Muscle strengthening exercises were started as patients were able to tolerate them.

### *Statistical analysis*

The mean, standard deviation, range, and percent values were used in the descriptive statistics. Categorical variables were summarized as a percentage of the total. To compare between groups, we used the chi-square test for the categorical variables. The independent samples t-test and Mann–Whitney U test were used in the comparison of quantitative data. Pre- to postoperative changes were evaluated using the paired samples t-test and Wilcoxon signed-rank test. All statistical analyses were performed using SPSS v24 (SPSS Inc., Armonk, NY, USA).

P-values < 0.05 were considered statistically significant.

## Results

Out of 47 potential patients treated with LC-DCP during the study period, 19 patients were excluded based on exclusion criteria and 28 patients were included in the study. Patients were divided into two groups according their fracture site in the tibia. Group 1 consisted of 13 patients and group 2 consisted of 15 patients. Twenty-three (82.1%) patients had high-energy

trauma [11 (39.2%) motor vehicle accidents, seven (25%) falls from a height, three (10.7%) fire weapon injuries, two (7.1%) blunt injuries] and five (17.8%) patients had low-energy trauma [four (14.2%) falls from standing and one (3.5%) cutting tool injury]. Table 1 shows the demographic characteristics of patients, mean follow-up time, mean operation time, and fracture patterns stratified by groups.

The mean bone union time, malunion rate, angulation in the sagittal and coronal planes on radiographs, and infection rate are shown in Table 2. Mean union time,

**Table 1.** Demographic characteristics of the patients.

Variable	Entire study population	Group 1	Group 2	P-value
Patient, number (%)	28 (100)	13 (46.4)	15 (53.6)	0.724
Age, years, SD	47.0 ± 15.7	48.0 ± 17.8	45.8 ± 13.5	0.717
Gender, number (%)				0.097
Female	5 (17.9)	1 (6.7)	4 (30.8)	
Male	23 (82.1)	14 (93.3)	9 (69.2)	
Fracture pattern, number (%)				0.136
Open	13 (46.4)	5 (33.3)	8 (61.5)	
Closed	15 (53.6)	10 (66.6)	5 (38.5)	
Operation time, minutes, SD	93.5 ± 31.9	92.0 ± 33.5	95.3 ± 31.2	0.786
Follow-up time, months, SD	18.3 ± 12.1	17.6 ± 11.7	19.1 ± 14.1	0.567

SD, standard deviation.

**Table 2.** Union, malunion, and infection rates.

Variable	Entire Study Population	Group 1	Group 2	P-value
Bone union time, months, SD	3.92 ± 1.27	3.66 ± 1.04	4.23 ± 1.48	0.250
Malunion, n (%)				0.262
Yes	6 (21.4)	2 (13.3)	4 (30.8)	
No	22 (78.6)	13 (86.7)	9 (69.2)	
Angulation in sagittal plane, extension degrees, SD	1.17 ± 4.14	1.46 ± 3.39	0.84 ± 4.99	0.701
Angulation in coronal plane, valgus degrees, SD	0.75 ± 2.63	0.93 ± 2.40	0.53 ± 2.96	0.700
Infection, n (%)				0.827
Yes	7 (25)	4 (26.7)	3 (23.1)	
No	21 (75)	11 (73.3)	10 (76.9)	

SD, standard deviation.

malunion rate, and mean operation length were not significantly different between distal fractures and midshaft fractures. No mechanical complications related to the plate occurred. None of the plates needed to be removed.

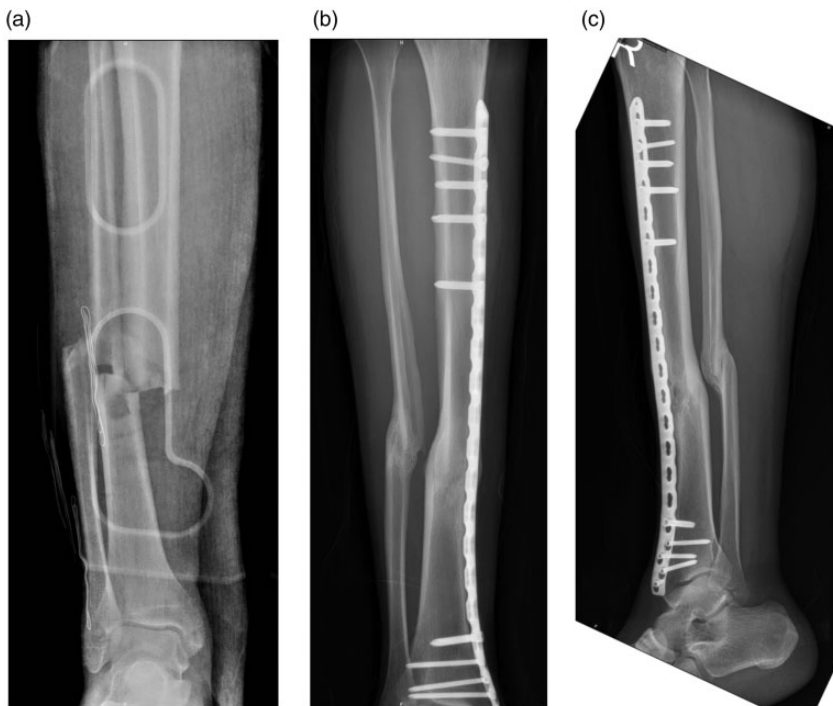
Twenty-seven (96.4%) patients had painless full weight bearing and a physiological gait pattern at 12 months after surgery. For all patients, mean ankle dorsiflexion, plantarflexion, inversion, and eversion were 18.4° (max: 20°, min: 10°), 43.6° (max: 50°, min: 35°), 32.4° (max: 35°, min: 28°) and 13° (max: 15°, min: 7°), respectively. Figure 1 and Figure 2 show case examples.

## Discussion

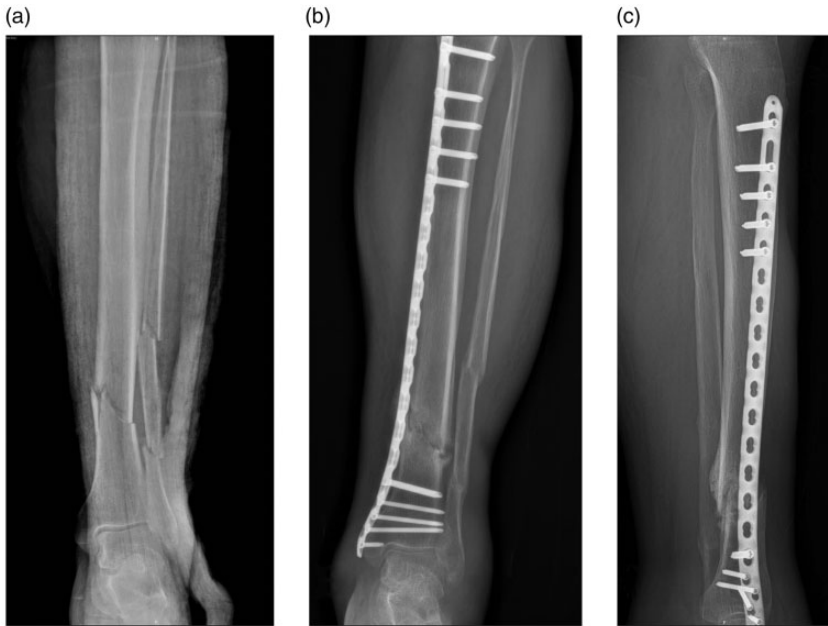The most important finding of this study was that osteosynthesis with the LC-DCP

using MIPO technique had acceptable union and complication rates in the treatment of patients with short oblique diaphyseal tibia fractures. We also found no effect of fracture location (midshaft or distal 1/3) on outcomes.

For distal tibial shaft fractures, using a bridge plate with relative stability in a simple fracture pattern is a valid treatment option that has limited soft-tissues damage.<sup>14</sup> Two stability systems can be used for fracture fixation with a plate. A relative stability construct is a bridge plate and an absolute stability construct is a neutralization plate with a lag screw.<sup>14</sup> With absolute stability, interfracture micro-movements are limited for faster fracture healing, and relative stability with a bridge plate allows indirect ossification.<sup>15</sup> The amount of interfracture movement



**Figure 1.** Representative X-rays of a patient in the middle 1/3 tibial shaft fracture group. (a) Pre-operative anteroposterior, (b) Final follow-up anteroposterior, (c) Final follow-up lateral.



**Figure 2.** Representative X-rays of a patient in the distal 1/3 tibial shaft fracture group. (a) Pre-operative anteroposterior (b) Final follow-up anteroposterior, (c) Final follow-up lateral.

and the size of the fracture gap play a critical role in the time to fracture healing.<sup>3,16</sup> Horn et al. reported on the role of the lag screw on fracture healing in 41 patients, including 27 patients who underwent MIPO technique compared with 14 patients treated with conventional open reduction and internal fixation, and reported faster fracture healing with lag screw application.<sup>17</sup> None of our patients had nonunion with the MIPO technique, and we think that nonunion is the most devastating complication after tibial shaft fractures. The fracture healing time in our study was similar to previous reports.

A previous systemic review and meta-analysis by Liu et al. showed that patients who underwent MIPO had less malunion, and IMN did not have advantages in radiation time, nonunion or delayed union rate, union time, or operation time compared with MIPO. Whether in closed or open fractures, IMN appeared to have a lower

incidence of wound complications, but MIPO was recommended for the treatment of distal tibia fractures for its advantage in preventing malunion.<sup>2</sup> Our findings also showed that union, nonunion, and malunion rates were acceptable for both distal and midshaft fractures. Although IMN is very common, plate osteosynthesis outcomes with the MIPO technique are also acceptable with respect to healing rate and time.

Malunion was defined as a varus/valgus deformity  $>5^\circ$  in the coronal plane, anterior/posterior angulation  $>10^\circ$  in the sagittal plane, a rotational deformity  $>10^\circ$ , or shortening  $>10$  mm.<sup>18</sup> Although the incidence of malunion in a meta-analysis of randomized controlled trials by Xiao et al.<sup>2</sup> was not significantly different between the two groups, the pooled data pointed to a higher incidence of malunion in the IMN group compared with the MIPO group. Our results showed no difference in terms of malunion between the midshaft and

distal tibial regions. Our overall results are similar to those of previous studies.

This study had some limitations, including the absence of long-term follow-up and the small sample size. This study was conducted in a regional trauma center where many tibia fractures are treated. We analyzed all tibia fractures between 2015 and 2019 and detected 338 tibial shaft fractures. Most of these did not have a simple fracture pattern because of the high-energy mechanisms, with most having a complex fracture pattern. Thus, we included only 28 patients with AO/OTA type 42A2 fractures, as mentioned in the methods section. Because of that, our sample size was not large. Long-term, prospective, multicenter, randomized clinical trials with a larger sample size are needed to further confirm our findings.

## Conclusions

MIPO may be an effective method for the treatment of short oblique diaphyseal tibia fractures, and results in few complications. Both distal and midshaft fractures have similar union and malunion rates. Medial anatomical plates offer the advantage of multiple locking screw holes in the wide distal part of the implant, which permits introducing an adequate number of screws in a short segment, which would otherwise require a longer incision with regular plates. An interfragmentary lag screw may not be mandatory to achieve stability and compression at the fracture site if eccentric cortical screws are used.

## Declaration of conflicting interest

The author(s) declared no potential conflicts of interest with respect to the research, authorship, and/or publication of this article.

## Funding

This research received no specific grant from any funding agency in the public, commercial, or not-for-profit sectors.

## ORCID iDs

Gokay Eken  <https://orcid.org/0000-0001-9447-4749>

Teoman Atici  <https://orcid.org/0000-0003-3063-1930>

## References

1. Larsen P, Elsoe R, Hansen SH, et al. Incidence and epidemiology of tibial shaft fractures. *Injury* 2015; 46: 746–750.
2. Liu XK, Xu WN, Xue QY, et al. Intramedullary nailing versus minimally invasive plate osteosynthesis for distal tibial fractures: a systematic review and meta-analysis. *Orthop Surg* 2019; 11: 954–965.
3. Vicenti G, Bizzoca D, Nappi VS, et al. The impact of lag screw in the healing time of distal tibia fractures treated with minimally invasive plate osteosynthesis: a randomized clinical trial. *Injury* 2020; 51 Suppl 3: S80–S85.
4. Kuo LT, Chi CC and Chuang CH. Surgical interventions for treating distal tibial metaphyseal fractures in adults. *Cochrane Database Syst Rev* 2015; 3: CD010261.
5. Wenger R, Oehme F, Winkler J, et al. Absolute or relative stability in minimal invasive plate osteosynthesis of simple distal meta or diaphyseal tibia fractures? *Injury* 2017; 48: 1217–1223.
6. Barcak E and Collinge CA. Metaphyseal distal tibia fractures: a cohort, single-surgeon study comparing outcomes of patients treated with minimally invasive plating versus intramedullary nailing. *J Orthop Trauma* 2016; 30: e169–e174.
7. Lefaivre KA, Guy P, Chan H, et al. Long-term follow-up of tibial shaft fractures treated with intramedullary nailing. *J Orthop Trauma* 2008; 22: 525–529.
8. Perren SM, Fernandez A and Regazzoni P. Understanding fracture healing biomechanics based on the “strain” concept and its clinical applications. *Acta Chir Orthop Traumatol Cech* 2015; 82: 253–260.
9. Claes L, Reusch M, Gockelmann M, et al. Metaphyseal fracture healing follows similar biomechanical rules as diaphyseal healing. *J Orthop Res* 2011; 29: 425–432.

10. Fan W, Crawford R and Xiao Y. Structural and cellular differences between metaphyseal and diaphyseal periosteum in different aged rats. *Bone* 2008; 42: 81–89.
11. Baud A, Flecher X, Rochwerger RA, et al. Comparing the outcomes of the induced membrane technique between the tibia and femur: retrospective single-center study of 33 patients. *Orthop Traumatol Surg Res* 2020; 106: 789–796.
12. Salem KH. Critical analysis of tibial fracture healing following unreamed nailing. *Int Orthop* 2012; 36: 1471–1477.
13. Song X, Huang X, Yakufu M, et al. Minimally invasive plate osteosynthesis or conventional intramedullary nailing for distal tibial fractures: A cohort study protocol. *Medicine (Baltimore)* 2020; 99: e21779.
14. Hasenboehler E, Rikli D and Babst R. Locking compression plate with minimally invasive plate osteosynthesis in diaphyseal and distal tibial fracture: a retrospective study of 32 patients. *Injury* 2007; 38: 365–370.
15. Baumgaertel F, Buhl M and Rahn BA. Fracture healing in biological plate osteosynthesis. *Injury* 1998; 29: C3–C6.
16. Jagodzinski M and Krettek C. Effect of mechanical stability on fracture healing—an update. *Injury* 2007; 38: S3–S10.
17. Horn C, Dobeles S, Vester H, et al. Combination of interfragmentary screws and locking plates in distal meta-diaphyseal fractures of the tibia: a retrospective, single-centre pilot study. *Injury* 2011; 42: 1031–1037.
18. Wani IH, Ul Gani N, Yaseen M, et al. Operative management of distal tibial extra-articular fractures - intramedullary nail versus minimally invasive percutaneous plate osteosynthesis. *Ortop Traumatol Rehabil* 2017; 19: 537–541.