



doi • 10.5578/tt.70045  
 Tuberk Toraks 2020;68(3):285-292  
 Geliş Tarihi/Received: 24.12.2019 • Kabul Ediliş Tarihi/Accepted: 03.10.2020

KLİNİK ÇALIŞMA  
 RESEARCH ARTICLE

# Diagnostic performance of EBUS-TBNA and its interrelation with PET-CT in patients with extra-thoracic malignancies

Ezgi DEMİRDÖĞEN<sup>1</sup>(ID)  
 Ahmet URSAVAŞ<sup>1</sup>(ID)  
 Özge AYDIN  
 GÜÇLÜ<sup>2</sup>(ID)  
 Nilüfer Aylin  
 ACET ÖZTÜRK<sup>1</sup>(ID)  
 Güven ÖZKAYA<sup>3</sup>(ID)  
 Mehmet KARADAĞ<sup>1</sup>(ID)

<sup>1</sup> Department of Chest Diseases, Faculty of Medicine, Uludag University, Bursa, Turkey

<sup>1</sup> Uludağ Üniversitesi Tıp Fakültesi, Göğüs Hastalıkları Anabilim Dalı, Bursa, Türkiye

<sup>2</sup> Clinic of Chest Diseases, Boyabat 75<sup>th</sup> Year State Hospital, Sinop, Turkey

<sup>2</sup> Boyabat 75. Yıl Devlet Hastanesi, Göğüs Hastalıkları Kliniği, Sinop, Türkiye

<sup>3</sup> Department of Biostatistics, Faculty of Medicine, Uludag University, Bursa, Turkey

<sup>3</sup> Uludağ Üniversitesi Tıp Fakültesi, Biyoistatistik Anabilim Dalı, Bursa, Türkiye

\* Presented at TRS Annual Congress 2019 in Bodrum, Turkey.

## ABSTRACT

### Diagnostic performance of EBUS-TBNA and its interrelation with PET-CT in patients with extra-thoracic malignancies

**Introduction:** Endobronchial ultrasound-guided transbronchial needle aspiration (EBUS-TBNA) is a well-established diagnostic tool for lung cancer, sarcoïdosis, and suspected metastatic extra-thoracic malignancy (ETM). Patients with primary ETM often have hypermetabolic mediastinal/hilar lymph node enlargement in the PET-scan done for initial staging or post treatment follow-up. We aimed to determine the diagnostic performance of EBUS-TBNA and the relationship between PET-SUV values and diagnosis of malignancy metastasis in patients with ETM.

**Materials and Methods:** Results of EBUS-TBNA in ETM patients with suspected MLN metastasis were retrospectively analysed (May 2016 to July 2019). Non-malign results were confirmed for surgery or clinical/radiological follow-up. Lymph nodes with a high FDG-uptake (SUV > 2.5, MLN) were reported as suspicious for metastasis.

**Results:** Of the 588 EBUS procedures, 109 were included in the analysis. Patient' mean age was 62.5 ± 10.1 years; there were 35 men and 74 women. Primary malignancies were breast cancer in 33, gastrointestinal in 23, female

**Cite this article as:** Demirdöğen E, Ursavaş A, Aydın Güçlü Ö, Acet Öztürk NA, Özkaya G, Karadağ M. Diagnostic performance of EBUS-TBNA and its Interrelation with PET-CT in patients with extra-thoracic malignancies. Tuberk Toraks 2020;68(3):285-292.

## Yazışma Adresi (Address for Correspondence)

Dr. Ezgi DEMİRDÖĞEN  
 Uludağ Üniversitesi Tıp Fakültesi,  
 Göğüs Hastalıkları Anabilim Dalı,  
 BURSA - TÜRKİYE  
 e-mail: demirdogenezgi@gmail.com

genital tract in 17, head and neck in 14, genitourinary cancer in 13, malignant melanoma in 6, sarcoma in 2 and kaposi sarcoma in 1. According to EBUS-TBNA smear and cell block histopathologic evaluations, 16 patients' results (14.7%) were malignant compatible with metastasis of ETM. Among the 93 patients with non-malignant diagnosis, EBUS-TBNA revealed a granulomatous lymphadenitis compatible with sarcoid reaction in 7 and tuberculosis in 2. A total of 9 patients underwent surgical procedures after EBUS-TBNA, with a definitive histological diagnosis of granulomatous lymphadenitis in 2, malignancy in 5 and, reactive lymph node in 2. Overall sensitivity, specificity, positive predictive value, negative predictive value and diagnostic accuracy of EBUS-TBNA were 76.19% (95% CI 52.83-91.78), 100% (95% CI 95.89-100.00), 100%, 94.62% (95% CI 89.12-97.12) and 95.4%, respectively.

**Conclusion:** EBUS-TBNA sampling has high diagnostic performance. Histopathological confirmation requirement for MLN should be kept in mind in patients with ETM, even they have negative EBUS results.

**Key words:** Endobronchial ultrasound; transbronchial needle aspiration; extra-thoracic malignancy; PET-CT; diagnostic performance

## ÖZ

### Ekstra-toraksik maligniteli hastalarda EBUS-TBİA tanı değeri ve PET-BT ile ilişkisi

**Giriş:** Endobronşyal ultrason-kılavuzluğunda transbronşyal iğne aspirasyonu (EBUS-TBİA), akciğer kanseri, sarkoidoz ve metastatik ekstra-toraksik malignitelerde (ETM) iyi tanımlanmış bir tanı yöntemidir. Primer ETM evrelemesi ve tedavi sonrası takipte, mediastinal/hiler lenf nodu (MLN) genişlemesi sık görülmektedir. ETM tanısı olan hastalarda EBUS-TBİA tanı performansı, PET-SUV değerleri ile malign metastaz tanısı arasındaki ilişkiyi araştırmayı hedefledik.

**Materyal ve Metod:** Şüpheli malign metastaz olan ETM hastalarında yapılan EBUS-TBİA sonuçları retrospektif olarak analiz edildi (Mayıs 2016-Temmuz 2019). Malign olmayan sonuçlar cerrahi veya klinik/radyolojik takip ile konfirme edildi. Yüksek FDG-uptake olan (SUV > 2.5, MLN) lenf nodları metastaz şüpheli olarak raporlandı.

**Bulgular:** Toplam 588 EBUS işleminden 109'u analize dahil edildi. Hastaların ortalama yaşı  $62.5 \pm 10.1$ ; 35'i erkek, 74'ü kadın idi. Primer malignitelerin, 33'ü meme kanseri, 23'ü gastrointestinal, 17'si kadın genital sistem, 14'ü baş-boyun, 13'ü genitüriner kanser, 6'sı malign melanom, 2'si sarkom ve 1'i kaposi sarkomu idi. EBUS-TBİA yayma ve hücre bloğu histopatolojik sonuçlarına göre 16 hastada (%14.7) ETM metastazı ile uyumlu malignite saptandı. Malign olmayan 93 hastadan 7'sinde sarkoid reaksiyon ile uyumlu granülomatöz lenfadenit, 2'sinde tüberküloz, 5'inde malignite bulundu. EBUS-TBİA sonrası cerrahi ile toplam 9 hastanın 2'sinde granülomatöz lenfadenit, 5'inde malignite ve 2'sinde reaktif lenf nodu saptandı. EBUS-TBİA için toplam duyarlılık, özgüllük, pozitif prediktif değer, negatif prediktif değer ve tanı doğruluğu, sırasıyla %76.19 (%95 GA 52.83-91.78), %100 (%95 GA 95.89-100.00), %100, %94.62 (%95 GA 89.12-97.12) ve %95.4 olarak saptandı.

**Sonuç:** EBUS-TBİA örnekleme tanı performansı yüksek bir yöntemdir. Negatif EBUS sonuçları olsa da, MLN genişlemesi olan ETM tanılı olgularda histopatolojik doğrulama gerekliliği akılda tutulmalıdır.

**Anahtar kelimeler:** Endobronşyal ultrason; transbronşyal iğne aspirasyonu; ekstra-toraksik malignensi; PET-BT; tanı performansı

## INTRODUCTION

Endobronchial ultrasound-guided transbronchial needle aspiration (EBUS-TBNA) is a well-established diagnostic tool for lung cancer, sarcoidosis, and suspected metastatic extra-thoracic malignancy (ETM). The most common solid tumours include breast, head and neck, colorectal, genitourinary, oesophagus, melanoma and sarcoma (1-5). Mediastinal/hilar lymph node (MLN) enlargement is common in follow-up patients with previously treated malignancies.

Positron emission tomography with 18-fluorodeoxyglucose (PET)- computed tomography (CT), as a non-invasive method, has high sensitivity in the determination of MLNs. The approach to PET-positive MLN in the initial diagnosis or follow-up of cancer post treatment presents certain challenges. In practice, while a low SUV (standardized uptake values) needs tissue confirmation, a high SUV is highly suggestive of

malignancy. In general, an SUV exceeding 2.5 in the MLN is considered highly suggestive of an active process, which has to be clinically correlated to define the risk of malignancy (6). However, due to high rates of false positivities, especially when granulomatous and inflammatory diseases are involved, histological verification is often required with more invasive procedures, such as mediastinoscopy or video-assisted thoracoscopic surgery (VATS) (7). EBUS-TBNA presents a minimally invasive alternative to mediastinoscopy. This procedure has few associated complications, is cost effective, and provides access to the hilar, interlobar and subcarinal lymph nodes (8). Additionally, it has much higher sensitivity and specificity than conventional TBNA for the assessment of mediastinal and hilar lymph nodes (9).

We aimed to determine the diagnostic performance of EBUS-TBNA and the relationship between PET-SUV

values and diagnosis of MLNs metastasis with EBUS-TBNA in patients with ETM.

## MATERIALS and METHODS

All EBUS-TBNA cases performed from May 2016 to July 2019 were retrospectively reviewed. Results of EBUS-TBNA in ETM patients with suspected hilar and/or mediastinal metastasis were analyzed. Patients diagnosed with benign reactive adenopathy by EBUS-TBNA subsequently underwent surgery or clinical/radiological follow-up. Clinical and radiological follow-up period was noted according to patient's medical records.

Before the procedure, all patients underwent detailed clinical evaluation, laboratory tests (complete blood count, liver and kidney function tests), chest radiograph and PET-CT scan. PET-CT imaging was performed using a Biograph 6 LSO scanner (Siemens Medical Systems, Erlangen, Germany). SUV values were calculated using body weight and pathologic metabolic activity foci were evaluated visually and quantitatively. Lymph nodes with high FDG uptake (SUV > 2.5, MLNs) were reported as suspicious for metastasis.

The MLNs were sampled with a convex probe EBUS (7.5 MHz, BFUC180F; Olympus, Tokyo, Japan), guided TBNA from various mediastinal and hilar locations under conscious sedation, using midazolam, propofol and remifentanyl. Using "spray as you go" method, topical anaesthesia was applied with 10% lidocaine spray to the vocal cords and 2% lidocaine to the airways (maximum 8 mg/kg). All EBUS procedures were performed on patients by two experienced pulmonologists. All EBUS accessible lymph nodes were sampled, regardless of FDG avidity. At least 3 real-time guided punctures were made in each MLN, with a 22-gauge EBUS needle (NA-201SX-4022; Olympus, Tokyo, Japan). Samples were simultaneously expressed onto glass slides, smeared and air-dried for cytology, and expelled into liquid fixatives (mixture of formaldehyde and alcohol) for cell block processing and histological evaluation. Air dried smears were stained with a May-Grunwald Giemsa stain. All materials were evaluated by the same experienced cytopathologist. EBUS-TBNA samples were also sprayed with 0.9% NaCl from each patient and sent to the microbiology laboratory, for acid-resistant bacillus (ARB) microscopic examination and mycobacterium culture. Presence of mature and transformed lymphocytes, with or without a conclusive diagnosis, was defined 'adequate

sample'; while absence of lymphocytes or presence of scant cellularity, only blood or benign bronchial cells was defined 'inadequate sample' (10).

## Statistical Analysis

Statistical analyses were performed with IBM SPSS ver.23.0 (IBM Corp. Released 2015. IBM SPSS Statistics for Windows, Version 23.0. Armonk, NY: IBM Corp.). The results were presented as mean± standard deviation for continuous variables and as frequency and percentage for categorical variables. Diagnostic accuracies of PET-CT were compared with chi-square test. Diagnostic sensitivity, specificity, positive predictive value (PPV), negative predictive value (NPV) and accuracy were calculated using standard definitions. A p-value < 0.05 was considered as statistically significant.

## RESULTS

Of the 588 EBUS procedures, 109 were included in the analysis. Patients' mean age was 62.5 ± 10.1 years; 35 (32%) were men and 74 (68%) women. Primary malignancies were breast cancer in 33 (30.3%), gastrointestinal in 23 (21.1%), female genital tract in 17 (15.6%), head and neck in 14 (12.9%), genitourinary in 13 (12%), malignant melanoma in 6 (5.5%), sarcoma in 2 (1.8%) and Kaposi sarcoma in 1 (0.9%) (Figure 1). Median size of lymph nodes seen at EBUS-TBNA was 8.40 mm (2.80-23.40) for the short axis and 12.60 mm (4.30-31.40) for the long axis, with each node having undergone a median of 3 passes (range 1-6). Overall, 406 lymph nodes were sampled at 10 different stations from 109 patients (Table 1). All samples were adequate. Median length of time from ETM diagnosis to EBUS-TBNA procedure was 2 (0-18) years. According to EBUS-TBNA smear and cell block histopathologic evaluations, 16 patients' results (14.7%) were malignant compatible with metastasis of extrapulmonary cancer. Median follow-up duration was 6 (3-36) months in patients with benign EBUS-TBNA results. Among the 93 patients with non-malignant diagnosis, EBUS-TBNA revealed granulomatous lymphadenitis compatible with sarcoid reaction in 7 (6.4%), tuberculosis in 2 (1.8%) (culture positivity in addition to granulomatous lymphadenitis). Reactive lymph node was found in 84 (77.1%) of 93 patients with EBUS-TBNA. Among the patients who had reactive lymph node EBUS-TBNA results, a total of 9 patients underwent surgical procedures, (mediastinoscopy, mediastinotomy, VATS) with a definitive histological diagnosis of granulomatous lymphadenitis in 2 patients, metastasis of ETM in 5

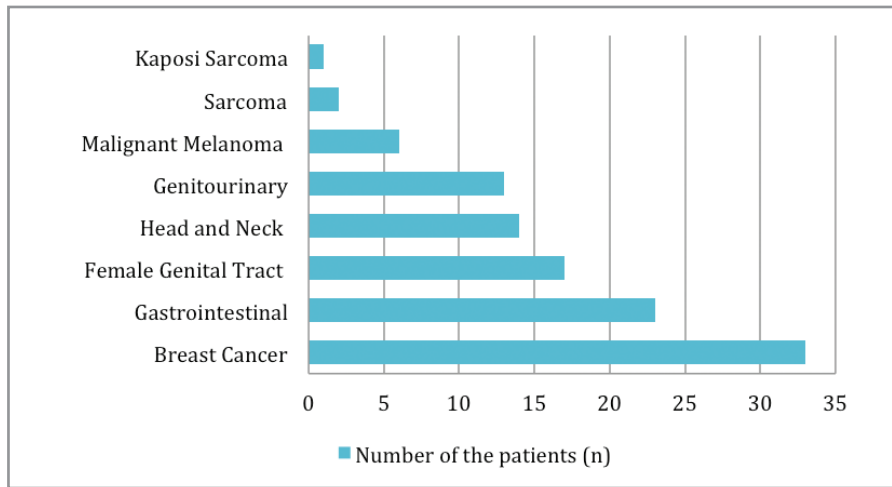


Figure 1. Distribution of primary malignancies.

Table 1. Distribution of sampled lymph nodes locations

Lymph nodes	N	%	Lymph node passes	Lymph node short axis	Lymph node long axis
7	105	96.3	3.26 ± 0.52	11.95 ± 3.92	17.90 ± 5.48
4R	73	67	3.19 ± 0.68	8.51 ± 3.35	14.12 ± 3.72
4L	37	33.9	3.16 ± 0.55	7.14 ± 3.99	10.25 ± 4.57
11R	71	65.1	2.91 ± 0.52	8.89 ± 2.77	12.30 ± 3.66
11L	71	65.1	3.02 ± 0.33	8.63 ± 2.50	13.40 ± 3.27
10R	35	32.1	2.97 ± 0.74	9.00 ± 3.50	12.10 ± 4.12
10L	6	5.5	3.00 ± 0.63	11.82 ± 5.06	18.00 ± 6.66
2R	5	4.6	3.40 ± 1.81	5.80 ± 1.13	9.95 ± 7.00
2L	2	1.8	4.00 ± 1.41	12.20 ± 1.64	18.66 ± 2.07
12L	1	0.9	3	8.50	11.80

Table 2. The relationship between PET-CT (according to the cut-off SUVmax value of 2.5) and malign positive EBUS pathology results

Pathology	7	4R	4L	11R	11L	10R	10L	2R	2L
SUVmax ≥ 2.5	5 (6.5%)	5 (9.1%)	2 (20%)	5 (12.8%)	2 (6.1%)	3 (11.5%)	2 (50%)	0	1 (100%)
SUVmax < 2.5	3 (15.8%)	1 (7.7%)	1 (4.2%)	0	0	1 (11.1%)	0	0	0

patients and, reactive lymph node in 2. The interrelation of PET-CT (according to the cut-off SUVmax value of 2.5) and positive EBUS-TBNA pathology results of lymph nodes are shown in Table 2. Overall sensitivity, specificity, positive predictive value (PPV), negative predictive value (NPV) and diagnostic accuracy of EBUS-TBNA were 76.19% (95% CI 52.83-91.78), 100% (95% CI 95.89-100.00), 100%, 94.62% (95% CI 89.12-97.12) and 95.4%, respectively (Table 3).

**DISCUSSION**

In this study, we aimed to evaluate the diagnostic performance of EBUS-TBNA, and the relationship between PET-SUV values and diagnosis of malignancy in patients with ETM. We determined overall sensitivity, specificity, PPV, NPV and diagnostic accuracy of EBUS-TBNA to be 76.19%, 100%, 100%, 94.62% and 95.4%, respectively.

**Table 3.** EBUS-TBNA malign diagnostic performance

	Final diagnosis		
	Negative	Positive	Total
EBUS negative	88	5	93
EBUS positive	0	16	16
Total	88	21	109

Sensitivity=16/21=76.19% (95% CI 52.83-91.78)  
 Specificity=88/88=100% (95% CI 95.89-100.00)  
 Negative predictive value=88/93=94.62% (95% CI 89.12-97.12)  
 Positive predictive value=16/16=100%  
 Accuracy=104/109=95.4%

Many recent articles have demonstrated the effectiveness and safety of EBUS-TBNA in different oncological settings (11,12). Being minimally invasive, the procedure has become the preferred approach for mediastinal staging in lung cancer, for tissue sampling of mediastinal and lung tumours, as well as for diagnosis of inflammatory and lymphoproliferative disorders (13,14). Yasufuku et al. reported EBUS-TBNA to have 94.6% sensitivity, 100% specificity and 89.5% NPV in lung cancer, with its accuracy being 96.3% (15). In comparison to mediastinoscopy, EBUS-TBNA and PET/CT have higher sensitivity, specificity and NPV in mediastinal staging (16). In cases that require further investigation, EBUS-TBNA, which allows easy "redo" sampling, proves also to be more advantageous than mediastinoscopy, in which repeat sampling is more difficult and less safe. Distribution of ETM in our study was breast cancer in 33 (30.3%), female genital tract in 17 (15.6%), head and neck in 14 (12.9%), gastrointes-

tinal in 23 (21.1%), genitourinary in 13 (12%), malignant melanoma in 6 (5.5%), sarcoma in 2 (1.8%) and Kaposi's sarcoma in 1 (0.9%) patients. Reference standard was radiological/clinical follow up or surgery as in previous studies (3-5,17-23). Tournoy et al analysed 92 patients with ETM with suspicion of mediastinal or hilar spread, who underwent EBUS-TBNA for diagnosis (4). Majority of the study population (nearly 70%) had head and neck carcinoma, colorectal carcinoma, and renal cell carcinoma. Twenty-nine cases (31.5%) were identified with benign conditions, such as reactive adenopathy, sarcoidosis, silicosis, and hamartoma, as a final diagnosis. Nine patients had surgical biopsies that showed metastatic disease. The sensitivity and NPV of EBUS-TBNA in detecting mediastinal spread of ETM were reported as 85% and 76%, respectively (4). Other studies also showed sensitivity rate of 78.2-95.7% (Table 4). In the present study, the sensitivity of EBUS-TBNA in ETM patients with suspicion of medias-

**Table 4.** Summary of the literature for EBUS-TBNA diagnostic performance in ETM patients with mediastinal/hilar lymph node

Study	No of patients	Sensitivity (%)	Specificity (%)	NPV (%)	Diagnostic accuracy (%)
Navani et al., 2011/consecutive cases (3)	161	87	-	73	88
Tournoy et al., 2011/consecutive cases (4)	92	85	-	76	-
Song et al., 2011/consecutive cases (17)	57	88	-	85	93
Park et al., 2011/retrospective (18)	59	81	100	-	-
Parmaksız et al., 2012/ consecutive cases (20)	48	89.2	100	86.9	93.7
Özgül et al., 2013/retrospective (19)	40	90	100	90.9	95
Sanz-Santos et al., 2013/retrospective (5)	117	86.4	-	75	90.3
Şentürk et al., 2014/consecutive cases (22)	54	93	100	92.6	96.3
Erer et al., 2016/retrospective (21)	63	78.2	100	88.3	91.8
Tertemiz et al., 2017/retrospective (23)	91	90.2	100	92.5	95.6
Guarize et al., 2017/retrospective (2)	176	95.7	100	92.3	97.2
This study, 2019	109	76.19	100	94.6	95.4

tinal metastasis was 76.19%, which is similar in research of Erer et al (21). In a study by Song et al, of the 57 patients with proven or suspicious ETM, 35 (61.4%) were confirmed to have malignancies, while EBUS-TBNA identified malignancy in 30 patients (17). In the same study, overall cancer prevalence was found to be 61%, while diagnostic sensitivity, accuracy and NPV of EBUS-TBNA per patient were 88%, 93% and 85%, respectively (17). In another study, EBUS-TBNA was performed in patients with known extrapulmonary malignancies or suspected MLNs metastasis from unknown origin, for diagnostic purposes and its sensitivity and specificity, were determined to be 81%, 100% respectively (18). Approximately 30% of the cases with ETM can metastasize to the mediastinum, manifesting as MLNs (24). EBUS-TBNA is a safe, effective and accurate procedure for MLN sampling; however, negative findings may require mediastinoscopy for further investigation (25).

In our study, EBUS-TBNA smear and cell block histopathologic evaluations identified 16 patients (14.7%) to be malignant compatible with metastasis of ETM. Among the 93 patients with non-malignant diagnosis, EBUS-TBNA revealed granulomatous lymphadenitis compatible with sarcoid reaction in 7 cases and tuberculosis in 2. A total of 9 patients underwent surgical procedures after EBUS-TBNA, with a definitive histological diagnosis of granulomatous lymphadenitis in 2 and malignancy in 5 patients. Mehta et al showed that EBUS-TBNA revealed malignancy in 20/65 cases (30.76%), and benign diagnoses in 69% of the cases [(tuberculosis in 6/65 (9%), sarcoidosis 24/65 (37%) and reactive lymph nodes in 15/65 (23%)] (1). In one study, EBUS-TBNA sampling in ETM has shown that even for FDG avid cases, granulomas seen on histology had a 100% NPV (26). Granulomas seen on histology, in these cases, indicate a sarcoid-like inflammatory reaction or an undiagnosed pulmonary sarcoidosis. The association between granulomatous MLN inflammation and malignancy is described as a "sarcoid-like reaction". This is seen in malignancies such as lung cancer, cutaneous malignancies, testicular germ cell tumour, renal cell carcinoma, hepatocellular carcinoma and digestive tract cancer. Various hypotheses exist as to its cause, such as an immunological dysfunction related to cancer, or a side effect of cancer therapy. The phenomenon is also described in cancer patients treated with surgery alone, with an explanatory theory postulating that "antigenic shedding" from the tumour leads to granuloma formation (27-29). Lower NPVs

have also been reported for EBUS-TBNA performed due to suspicion of mediastinal metastasis in ETM, underscoring the importance of further investigation (3, 5). Moreover, it should be kept in mind that PET-CT positivity of mediastinal lymph nodes is nonspecific and occurs in benign and malignant conditions with similar frequency (30).

There are some limitations to our study. The retrospective design indicates that only clinically selected patients for EBUS-TBNA were included. Though consecutive patients were included to minimize this bias, features of patients directly referred for mediastinoscopy, outside of the study, were not known. Negative EBUS-TBNA results were not confirmed by surgical procedure in all patients. The data confirm the need for a surgical invasive investigation when EBUS-TBNA reveals a non-neoplastic diagnosis in highly suspect cases, in this subset of patients.

## CONCLUSION

EBUS-TBNA sampling has high diagnostic performance in suspicion of mediastinal metastasis in ETM patients. Although surgical histological confirmation is required in cases with a strong suspicion of metastasis, the safe and less invasive EBUS-TBNA should be used as an initial diagnostic tool in ETM patients. Surgical histopathological confirmation should be kept in mind in patients with ETM, even they have negative EBUS results.

## ACKNOWLEDGMENTS

We would like to acknowledge all participants who contributed their data to this research. All authors approved the final version of the manuscript.

**Ethics Committee Approval:** The approval for this study was obtained from Bursa Uludag University Faculty of Medicine Ethics Committee. (Decision no: 2017-2/11 Date: 14.02.2017).

## CONFLICT of INTEREST

There is no conflict of interest related to this study.

## AUTHORSHIP CONTRIBUTIONS

Concept/Design: All of authors

Analysis/Interpretation: ED, GÖ, AU, ÖAG

Data Acquisition: ED, NAAÖ, ÖAG, AU, MK

Writing: ED, ÖAG

Critical Revision: ED

Final Approval: All of authors

## REFERENCES

1. Mehta RM, Biraris P, Patil S, Singla A, Kallur K, Gasparini S. Utility of EBUS-TBNA in PET positive mediastinal lymph nodes in subjects with extra-thoracic malignancy. *PLoS One* 2019; 14(3): e0213437.
2. Guarize J, Casiraghi M, Donghi S, Casadio C, Diotti C, Filippi N, et al. EBUS-TBNA in PET-positive lymphadenopathies in treated cancer patients. *ERJ Open Res* 2017; 3(4): 00009-2017.
3. Navani N, Nankivell M, Woolhouse I, Harrison RN, Munavvar M, Oltmanns U, et al. Endobronchial ultrasound-guided transbronchial needle aspiration for the diagnosis of intrathoracic lymphadenopathy in patients with extrathoracic malignancy: a multicentre study. *J Thorac Oncol* 2011; 6(9): 1505-9.
4. Tournoy KG, Govaerts E, Malfait T, Dooms C. Endobronchial ultrasound-guided transbronchial needle biopsy for M1 staging of extrathoracic malignancies. *Ann Oncol* 2011; 22(1): 127-31.
5. Sanz-Santos J, Cirauqui B, Sanchez E, Andreo F, Serra P, Monso E, et al. Endobronchial ultrasound-guided transbronchial needle aspiration in the diagnosis of intrathoracic lymph node metastases from extrathoracic malignancies. *Clin Exp Metastasis* 2013; 30(4): 521-8.
6. Lowe VJ, Hoffman JM, DeLong DM, Patz EF, Coleman RE. Semiquantitative and visual analysis of FDG-PET images in pulmonary abnormalities. *J Nucl Med* 1994; 35(11): 1771-6.
7. Bakheet SM, Powe J. Benign causes of 18-FDG uptake on whole body imaging. *Semin Nucl Med* 1998; 28(4): 352-8.
8. Mehta HJ, Tanner NT, Silvestri G, Simkovich SM, Shamblin C, Shaftman SR, et al. Outcome of patients with negative and unsatisfactory cytologic specimens obtained by endobronchial ultrasound-guided transbronchial fine-needle aspiration of mediastinal lymph nodes. *Cancer Cytopathol* 2015; 123(2): 92-7.
9. Yan JH, Pan L, Chen XL, Chen JW, Yan LM, Liu B, et al. Endobronchial ultrasound versus conventional transbronchial needle aspiration in the diagnosis of mediastinal lymphadenopathy: a meta-analysis. *Springerplus* 2016; 5(1): 1716.
10. Cameron SE, Andrade RS, Pambuccian SE. Endobronchial ultrasound-guided transbronchial needle aspiration cytology: a state of the art review. *Cytopathology* 2010; 21(1): 6-26.
11. Cömert SŞ, Çağlayan B, Fidan A, Salepçi B, Doğan C, Demirhan R, et al. A comparison of endobronchial ultrasound-guided transbronchial needle aspiration and integrated positron emission tomography-computed tomography in the diagnosis of malignant mediastinal/hilar lymph nodes. *Turk J Thorac Cardiovasc Surg* 2012; 20: 843-49.
12. Kandemir Z, Sentürk A, Ozdemir E, Yildirim N, Hasanoğlu HC, Keskin M, et al. The evaluation of hypermetabolic mediastinal-hilar lymph nodes determined by PET/CT in pulmonary and extrapulmonary malignancies: correlation with EBUS-TBNA. *Turk J Med Sci* 2015; 45(6): 1234-42.
13. Kinsey CM, Arenberg DA. Endobronchial ultrasound-guided transbronchial needle aspiration for non-small cell lung cancer staging. *Am J Respir Crit Care Med* 2014; 189(6): 640-9.
14. Wahidi MM, Herth F, Yasufuku K, Shepherd RW, Yarmus L, Chawla M, et al. Technical aspects of endobronchial ultrasound-guided transbronchial needle aspiration: CHEST guideline and expert panel report. *Chest* 2016; 149(3): 816-35.
15. Yasufuku K, Chiyo M, Koh E, Moriya Y, Iyoda A, Sekine Y, et al. Endobronchial ultrasound guided transbronchial needle aspiration for staging of lung cancer. *Lung Cancer* 2005; 50(3): 347-54.
16. Warren WA, Hagaman JT. Endobronchial ultrasound-guided transbronchial needle aspiration for mediastinal staging in a community medical center. *Ann Am Thorac Soc* 2016; 13(10): 1802-7.
17. Song JU, Park HY, Jeon K, Koh WJ, Suh GY, Chung MP, et al. The role of endobronchial ultrasound-guided transbronchial needle aspiration in the diagnosis of mediastinal and hilar lymph node metastases in patients with extrapulmonary malignancy. *Intern Med* 2011; 50(21): 2525-32.
18. Park J, Jang SJ, Park YS, Oh YM, Shim TS, Kim WS, et al. Endobronchial ultrasound-guided transbronchial needle biopsy for diagnosis of mediastinal lymphadenopathy in patients with extrathoracic malignancy. *J Korean Med Sci* 2011; 26(2): 274-8.
19. Özgül MA, Çetinkaya E, Tutar N, Özgül G, Onaran H, Bilaçeroğlu S. Endobronchial ultrasound-guided transbronchial needle aspiration for the diagnosis of Intrathoracic lymphadenopathy in patients with extrathoracic malignancy: a study in a tuberculosis-endemic country. *J Cancer Res Ther* 2013; 9(3): 416-21.
20. Parmaksız ET, Çağlayan B, Salepci B, Comert SS, Kiral N, Fidan A, et al. The utility of endobronchial ultrasound-guided transbronchial needle aspiration in mediastinal or hilar lymph node evaluation in extrathoracic malignancy: Benign or malignant? *Ann Thorac Med* 2012; 7(4): 210-4.
21. Erer OF, Anar C, Erol S, Özkan S. The utility of EBUS-TBNA in mediastinal or hilar lymph node evaluation in extrapulmonary malignancy. *Turk J Med Sci* 2016; 46(1): 112-9.
22. Şentürk A, Kiliç H, Hezer H, Karaduman Yalçın F, Hasanoğlu HC. Endobronchial ultrasound-guided transbronchial needle biopsy for the diagnosis of mediastinal lymphadenopathy in patients with extrathoracic malignancies. *Turk J Med Sci* 2014; 44(6): 989-95.
23. Tertemiz KC, Alpaydin AO, Karacam V. The role of endobronchial ultrasonography for mediastinal lymphadenopathy in cases with extrathoracic malignancy. *Surg Endosc* 2017; 31(7): 2829-36.
24. Bono AV, Lovisolo JA. Renal cell carcinoma--diagnosis and treatment: state of the art. *Eur Urol* 1997; 31(Suppl 1): 47-55.

25. Gu P, Zhao Y-Z, Jiang L-Y, Zhang W, Xin Y, Han BH. Endobronchial ultrasound-guided transbronchial needle aspiration for staging of lung cancer: a systematic review and meta-analysis. *Eur J Cancer* 2009; 45(8): 1389-96.
26. Bellinger CR, Sharma D, Ruiz J, Parks C, Dotson T, Haponik EF. Negative predictive value of granulomas on EBUS-TBNA in suspected extrathoracic malignancy. *Lung* 2016; 194(3): 387-91.
27. Brincker H. Sarcoid reactions in malignant tumours. *Cancer Treat Rev* 1986; 13(3): 147-56.
28. Yamasawa H, Ishii Y, Kitamura S. Concurrence of sarcoidosis and lung cancer. A report of four cases. *Respiration* 2000; 67(1): 90-3.
29. Parra ER, Canzian M, Saber AM, Coêlho RS, Rodrigues FG, Kairalla RA, et al. Pulmonary and mediastinal "sarcoidosis" following surgical resection of cancer. *Pathol Res Pract* 2004; 200(10): 701-5.
30. Gan Q, Stewart JM, Valik E, Eapen G, Caraway NP. Cytologic evaluation of positron emission tomography-computed tomography-positive lymph nodes sampled by endobronchial ultrasound-guided transbronchial needle aspiration: experience at a large cancer center. *Arch Pathol Lab Med* 2019; 143(10): 1265-70.