

1-1-2017

Thromboelastographic evaluation of hemostatic functionin dogs with dilated cardiomyopathy

ZEKİ YILMAZ

MERİÇ KOCATÜRK

OYA ERALP İNAN

PINAR LEVENT

Follow this and additional works at: <https://journals.tubitak.gov.tr/veterinary>



Part of the [Animal Sciences Commons](#), and the [Veterinary Medicine Commons](#)

Recommended Citation

YILMAZ, ZEKİ; KOCATÜRK, MERİÇ; İNAN, OYA ERALP; and LEVENT, PINAR (2017) "Thromboelastographic evaluation of hemostatic functionin dogs with dilated cardiomyopathy," *Turkish Journal of Veterinary & Animal Sciences*: Vol. 41: No. 3, Article 9. <https://doi.org/10.3906/vet-1608-4>
Available at: <https://journals.tubitak.gov.tr/veterinary/vol41/iss3/9>

This Article is brought to you for free and open access by TÜBİTAK Academic Journals. It has been accepted for inclusion in Turkish Journal of Veterinary & Animal Sciences by an authorized editor of TÜBİTAK Academic Journals. For more information, please contact academic.publications@tubitak.gov.tr.

Thromboelastographic evaluation of hemostatic function in dogs with dilated cardiomyopathy

Zeki YILMAZ¹, Meriç KOCATÜRK¹, Oya ERALP İNAN^{2*}, Pınar LEVENT¹

¹Department of Internal Medicine, Faculty of Veterinary Medicine, Uludağ University, Bursa, Turkey

²Medical and Surgical Experimental Animal Practice and Research Center, Eskişehir Osmangazi University, Eskişehir, Turkey

Received: 02.08.2016 • Accepted/Published Online: 06.02.2017 • Final Version: 12.06.2017

Abstract: This study aimed to evaluate the hemostatic function by thromboelastography (TEG) and determine if there was an association between the changes in hemostatic parameters and serum cardiac troponin I (cTnI) in dogs with dilated cardiomyopathy (DCM). DCM was diagnosed by echocardiography in 19 dogs. Ten healthy dogs were selected as controls. Myocardial injury was confirmed by increased serum cTnI levels. Coagulation was assessed by TEG evaluating clot kinetics (reaction time [R] and kinetic time [K]), clot strengthening (alpha [α] angle and G value), platelet function (maximum amplitude [MA] and coagulation-index [CI]), clot stability (LY30, the percentage of lysis 30 min after MA), and global clotting times (activated partial thromboplastin time [aPTT] and prothrombin time [PT]). Dogs with DCM had higher R and K times but lower MA, α -angle, G, and CI compared to controls ($P < 0.05$). LY30 and PT did not statistically differ between groups, but the aPTT in dogs with DCM was higher than that of the controls. Serum cTnI (median [range], ng/mL) was higher in dogs with DCM (0.25 [0.13–3.1]) than in healthy dogs (0.03 [0.01–0.06]). There was no statistical relation between cTnI and coagulation parameters. This study showed that alterations of the coagulation status in dogs with DCM could develop independently of serum cTnI elevations.

Key words: Dilated cardiomyopathy, thromboelastography, hemostasis, cardiac troponin I, dog

1. Introduction

Cardiological problems are one of the most common health problems for humans but are also prevalent in elderly dogs and cats. Dilated cardiomyopathy (DCM) is frequently diagnosed in canine veterinary practice (1). There are two forms of DCM: nonovert (asymptomatic, preclinical, or occult) DCM and overt (symptomatic) DCM. In dogs with the nonovert form, there are no noticeable clinical symptoms, but dogs with overt DCM suffer from exercise intolerance, coughing, abdominal distention (ascites), and tachypnea (2,3). DCM has been diagnosed according to the guidelines proposed by the European Society of Veterinary Cardiology (ESVC) taskforce, which include a scoring system for echocardiographic findings of left-ventricular (LV) dilatation, reduced systolic function, and increased sphericity of the LV (1,4).

DCM is an irreversible and progressive disease of the heart muscles and is often complicated by heart failure, pulmonary edema, ascites, cardiorenal syndrome, and thromboembolic disorders (5,6). Such disorders threaten long-term survival even if the patient receives thrombolytic medication (7). As it is well known, vascular abnormalities,

dilated cardiac chambers, low cardiac output, and blood stasis can cause flow abnormalities that predispose to hemostatic disorders in patients with heart failure (7,8). Thus, early diagnosis of heart disease is the first step in successfully protecting against thromboembolism (increased clot formation or hypercoagulation) in these patients (7).

Compared with traditional coagulation tests such as prothrombin time (PT) and activated partial thromboplastin time (aPTT), thromboelastography (TEG) has been accepted as a sensitive and useful tool for evaluating coagulation abnormalities like hypercoagulopathy, hypocoagulopathy, and disseminated intravascular coagulation in dogs (9,10). PT and aPTT values indicate whether or not there are any abnormalities in extrinsic (PT), intrinsic (aPTT), or common pathways (both) of the coagulation cascade, but TEG has been used to characterize the whole clotting cascade from initiation of clot formation to fibrinolysis (9). TEG evaluates clot kinetics (measured by reaction time [R] and kinetic time [K]), clot strengthening (measured by alpha [α] angle and G value), platelet function (measured by maximum

* Correspondence: oeralp@ogu.edu.tr

amplitude [MA] and coagulation index [CI]), and clot stability (measured by LY30, the percentage of lysis 30 min after MA) (11). The R-value most closely represents the intrinsic pathway of the coagulation system whereas K, α -angle, and MA values are related to the speed of clot formation and platelet number and function. LY30 is a measure of fibrinolysis and is determined primarily by the ability of plasmin to break down the formed clot (10–13).

Although hemostasis is traditionally evaluated with measurements of PT and aPTT in dogs with heart disease (9), there are no published data on TEG evaluation of hemostasis in dogs with DCM. Thus, the purpose of this study was to evaluate hemostatic functions by kaolin-activated TEG in dogs with DCM. It is well known that in dogs with heart disease the presence and severity of myocardial injury is assessed by the serum level of cardiac troponin I (cTnI), but data on how the presence of myocardial injury affects coagulation tests are not available yet (14–16). Therefore, we also investigated whether there was a relationship between changes in hemostatic parameters and the serum marker of myocardial injury (cTnI) in dogs.

2. Materials and methods

2.1. Animals

In this study, two groups were formed: a cardiac and a control group. For the cardiac group, 19 client-owned dogs with DCM were selected from patient records in a small animal hospital's cardiology unit (Department of Internal Medicine, Faculty of Veterinary Medicine, Uludağ University, Bursa). Dogs with no evidence of concurrent vector-borne pathogens (Anigen Rapid CaniV-4 and Leishmania Ab test kits, Bionote), no noninfectious systemic diseases (hypothyroidism, diabetes mellitus, hyperadrenocorticism, etc.), and no treatment during the previous week were included in the study. Dogs were of both sexes (9 males and 10 females) and various breeds including 4 Cavalier King Charles spaniels, 4 Golden retrievers, 4 Anatolian shepherd dogs, 3 Labrador retrievers, 3 terriers, and one Doberman. The dogs weighed between 12.4 and 57.5 kg and had a median age of 10 years.

The control group consisted of 10 healthy dogs, based on unremarkable clinicopathological evaluation (physical examination, hematological, and biochemistry evaluations) and seronegativity to common vector-borne pathogens (Anigen Rapid CaniV-4 and Leishmania Ab test kits, Bionote). The controls were of similar age, weight, and breed as those in the cardiac group.

Animal data in this study were collected retrospectively from hospital records, and all data consisted of the results of diagnostic procedures that were necessary during patient evaluations in the animal hospital.

2.2. Case selection

Only dogs with overt DCM were included in this study. According to the ACVIM/ECVIM Consensus Classification System (Stages A, B, C, and D), the dogs in this study were categorized as Stage C patients, defined as patients with past or current clinical signs of congestive heart failure. Stage C patients also fit the criteria of Class III, in which patients show clinical symptoms during routine activity as described by the modified New York Heart Association and International Small Animal Cardiac Health Council systems. Both systems include four different stages: from patients with asymptomatic heart disease (Class I) to patients with heart disease causing severe symptoms at rest (Class IV) (17).

The diagnosis of overt DCM was made primarily by Doppler echocardiographic examination in combination with clinical presentation and thoracic radiographic and electrocardiographic (ECG) findings, as suggested (1,18). Echocardiographic examinations, which were performed by two experienced academics (ZY and/or MK), included two-dimensional, M-mode, color flow imaging, and spectral Doppler measurements (Caris Plus, Esoate, Florence, Italy) with standard imaging techniques, for which 2.5–5, 5–7.5, and 8–10 MHz phased-array transducers were used. The dogs were not sedated during the ultrasound examinations and were gently restrained in right lateral recumbency on a table suitable for this purpose.

The echocardiographic diagnosis was made using the accepted criteria proposed by the ESVIC. Briefly, dogs with DCM showed the following: left-ventricular (LV) dilatation; reduced systolic function (lower fractional shortening); increased sphericity of the LV with or without biatrial enlargement; increased E point to septal separation (EPSS); arrhythmia, such as atrial fibrillation; increased preejection period (PEP); and LV ejection time (LVET) ratio. LV measurements were compared to normal published values for specific breeds. If there was no publication as a reference for a breed, results were compared with breeds of similar size and weight. Each of these echocardiographic findings was scored. Every dog with a total score above six points was included in the study (1).

2.3. Sample collection and measurements

Blood samples were collected before treatment from the brachiocephalic vein into vacutainer tubes containing K₂EDTA for a complete blood count (CBC). The tubes contained 3.2% sodium citrate (BD Vacutainer System, BD Diagnostics, NJ, USA) for hemostatic evaluations (11). To rule out infectious and noninfectious metabolic diseases, CBC and serum biochemistry analyses (comprehensive profile, Abaxis) were performed shortly after the blood collection using automatic analyzers (HM5 and VetScan,

Abaxis, Union City, CA, USA). Hemostatic functions were assessed by measurements of global clotting times (aPTT and PT) (automatic coagulation analyzer, VetScan VSpro, Abaxis) and TEG (TEG 5000, Haemonetics, Braintree, MA, USA), as previously described (10–12). Seven parameters of TEG were included for this study, as selected in previous studies (10,12,13): reaction time (R), coagulation time (K), alpha (α) angle, maximum amplitude (MA), G value, LY30 (percentage of lysis 30 min after MA), and coagulation index (CI).

2.4. Statistical analysis

Results were expressed as mean \pm SD. The results for each parameter were evaluated for approximate normality of distribution by using the Kolmogorov–Smirnov statistical test (SigmaStat, Version 3.0, GmbH, Erkrath, Germany). For two-group comparison, data were evaluated with Student's t-test. $P < 0.05$ was considered significant.

3. Results

3.1. Patient data

A total of 19 dogs met the criteria for overt DCM. There were five different purebred dog breeds. The median body weight was 32 kg (mean \pm SD: 40.5 \pm 22.3 kg), ranging from a 12.4 kg terrier to a 57.5 kg Turkish Anatolian sheep dog. The median age was 10 years (range: 5–15 years).

3.2. ECG and radiological findings

The most common clinical findings were murmurs of different severity from grade I to grade IV (19/19), weak pulse (11/19), mucosal pallor (10/19), ascites (8/19), jugular distension (6/19), and pulse deficit (5/19). ECG analysis showed cardiac arrhythmias in dogs with DCM; sinus tachycardia (9/19), atrial fibrillation (6/19), atrial or ventricular extra systoles (5/19), and left-bundle branches block (5/19) were the most common. Radiological examination revealed cardiac enlargement (increased vertebral heart scores), interstitial or alveolar pattern, and/or pleural effusion in dogs with DCM.

3.3. Echocardiography

Cardiological examinations confirmed the diagnostic features of overt DCM as described in Section 2.2. The median LVDD and LVDs (interquartile range) were 4.4 cm (3.9–4.9 cm) and 2.9 cm (2.6–3.3 cm) in the control group, but they were 6.7 cm (5.3–7.8 cm) and 4.5 cm (1.4–7.4 cm), respectively, in the cardiac group, with a significant difference between groups ($P < 0.05$ –0.001) (Table). The median and mean fractional shortening (FS) and ejection fraction (EF) percentages were lower ($P < 0.05$ –0.001) but the ratio of LA diameter to Ao diastolic diameter and EPSS value were higher ($P < 0.01$ –0.001) in dogs with DCM compared to those of dogs in the control group, as seen in the Table.

Table. M-mode measurements of left ventricle and its related parameters in healthy dogs and dogs with dilated cardiomyopathy (DCM).

Parameters	Control dogs, mean \pm SD	Dogs with DCM, mean \pm SD	P-value
RVDD, cm	0.84 \pm 0.11	2.59 \pm 0.91	<0.001
IVSD, cm	0.84 \pm 0.11	0.91 \pm 0.32	NS
LVDD, cm	4.50 \pm 0.32	6.66 \pm 1.04	<0.001
PWDD, cm	1.05 \pm 0.19	0.86 \pm 0.17	<0.05
IVSS, cm	1.23 \pm 0.13	1.06 \pm 0.34	NS
LVDS, cm	2.98 \pm 0.28	4.11 \pm 2.36	<0.05
PWSD, cm	1.18 \pm 0.32	1.07 \pm 0.21	NS
EF, %	69.8 \pm 4.7	47.6 \pm 26.7	<0.05
FS, %	32.5 \pm 3.8	15.2 \pm 4.9	<0.001
LA/Ao, ratio	1.12 \pm 0.19	1.99 \pm 0.69	<0.01
EPSS, cm	0.3 \pm 0.2	0.9 \pm 0.3	<0.001

RVDD: Right ventricular end diastole diameter; IVSD: interventricular septum end diastole diameter; LVDD: left-ventricular diastolic distension; PWDD: posterior wall diastolic diameter; IVSS: interventricular septum end systole diameter; LVDS: left-ventricular end-systolic diameter; PWSD: left-ventricular posterior wall systolic diameter; EF: ejection fraction; FS: fractional shortening; LA/Ao ratio: left atrial ratio to aortic diameter; EPSS: E point to septal separation.

3.4. Laboratory analysis

CBC and routine serum biochemistry profiles were within reference limits in dogs with DCM (data not shown). The serum cTnI level (ng/mL) was 0.06 (maximum), 0.01 (minimum), and 0.03 (median) in the controls and 3.1, 0.1, and 0.2 in dogs with DCM, respectively. The mean serum cTnI level was higher (0.95 ± 1.2 ng/mL, $P < 0.05$) in dogs with DCM than in the controls (0.03 ± 0.01 ng/mL), as shown in Figure 1.

Although aPTT was higher in dogs with DCM (118 ± 36 s, $P < 0.05$) than in the controls (84 ± 10 s), there was no statistical difference in PT between groups (15 ± 2 s vs. 16 ± 1 s). TEG parameters ranged from 1.8 to 6.6 min for R time, 0.9 to 10.7 min for K time, 10.6 to 76.3 degrees for α -angle, 12.7 to 67.6 mm for MA, 0.7 to 10.4 for G, 0.0 to 7.1 for LY30, and -9.0 to 4.8 for CI in dogs with DCM, as seen in Figure 2. TEG findings revealed that dogs with DCM had significantly higher R (3.7 ± 1.9 min) and K times (5.5 ± 4.9 min, $P < 0.05$) than the controls (1.5 ± 0.8 min and 1.1 ± 0.4 min, respectively). MA (38 ± 23 min.), α -angle (43 ± 26 degrees), G (4.4 ± 4.1 dyn/cm²), and CI values (-2.4 ± 6.1) were lower ($P < 0.05$) in dogs with DCM compared to the control group (63 ± 9 min, 75 ± 5 degrees, 9.2 ± 3.4 dyn/cm², and 4.2 ± 1.9 , respectively). LY30 did not statistically differ between the two groups. TEG profiles showed hypercoagulation, secondary fibrinolysis, or platelet dysfunction (hypocoagulation) in some cases of DCM (Figure 3). Pearson correlations showed that there was no statistical relation between the cTnI and coagulation parameters measured.

4. Discussion

This study has suggested for the first time that dogs with overt DCM without any concurrent diseases might have

a changed coagulation status based on PT, aPTT, and TEG measurements, independent of myocardial injury (evidenced by the increase in serum cTnI level).

Our data confirmed that DCM is one of the most common cardiac diseases in purebred, older, and giant breeds referred to animal hospitals. In the present study, the observed clinical (coughing, exercise intolerance, ascites), ECG (sinus tachycardia, atrial fibrillation, etc.), and radiological (cardiomegaly and pulmonary patterns) findings in dogs with DCM were compatible with those of the Stage C patient in the classification of heart failure, as proposed by the ESVC (4). In this study, the diagnosis of DCM was further confirmed based on the echocardiographic findings related to geometric (increased LV chamber size, increased EPSS, and LA/Ao) and functional (poor FS or EF) abnormalities, along with the cardiac arrhythmias shown in the Table and increased serum cTnI levels represented in Figure 1 (1,12,17).

Coagulation abnormalities have been reported in patients that show different severities of heart diseases in human (7,19) and veterinary medicine (8,10,20), and thus therapeutic approaches have been suggested to protect patients from these problems (17). Coagulation activation and related complications such as thromboembolism were reported, especially in cats with hypertrophic cardiomyopathy (17,21). In dogs, myxomatous mitral valve disease can also lead to alterations of hemostasis (20). In the present study, the observed changes in aPTT value showed the presence of abnormalities in the intrinsic and common pathways of the coagulation cascade (a tendency towards a hypocoagulable state) in dogs with DCM. There was also no statistical difference in PT values between groups, showing that extrinsic system abnormalities were not possible in these dogs.

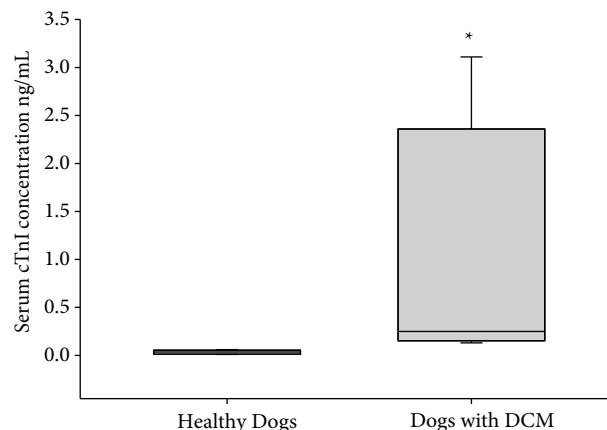


Figure 1. Comparison of serum cardiac troponin I (cTnI) between control (healthy) dogs and dogs with dilated cardiomyopathy (DCM). Data are presented as boxes and whiskers. Each box includes the interquartile range, whereas the line within a box represents the median; the whiskers represent the range and extend to a maximum of 1.5 times the interquartile range. * $P < 0.05$, as compared to healthy controls.

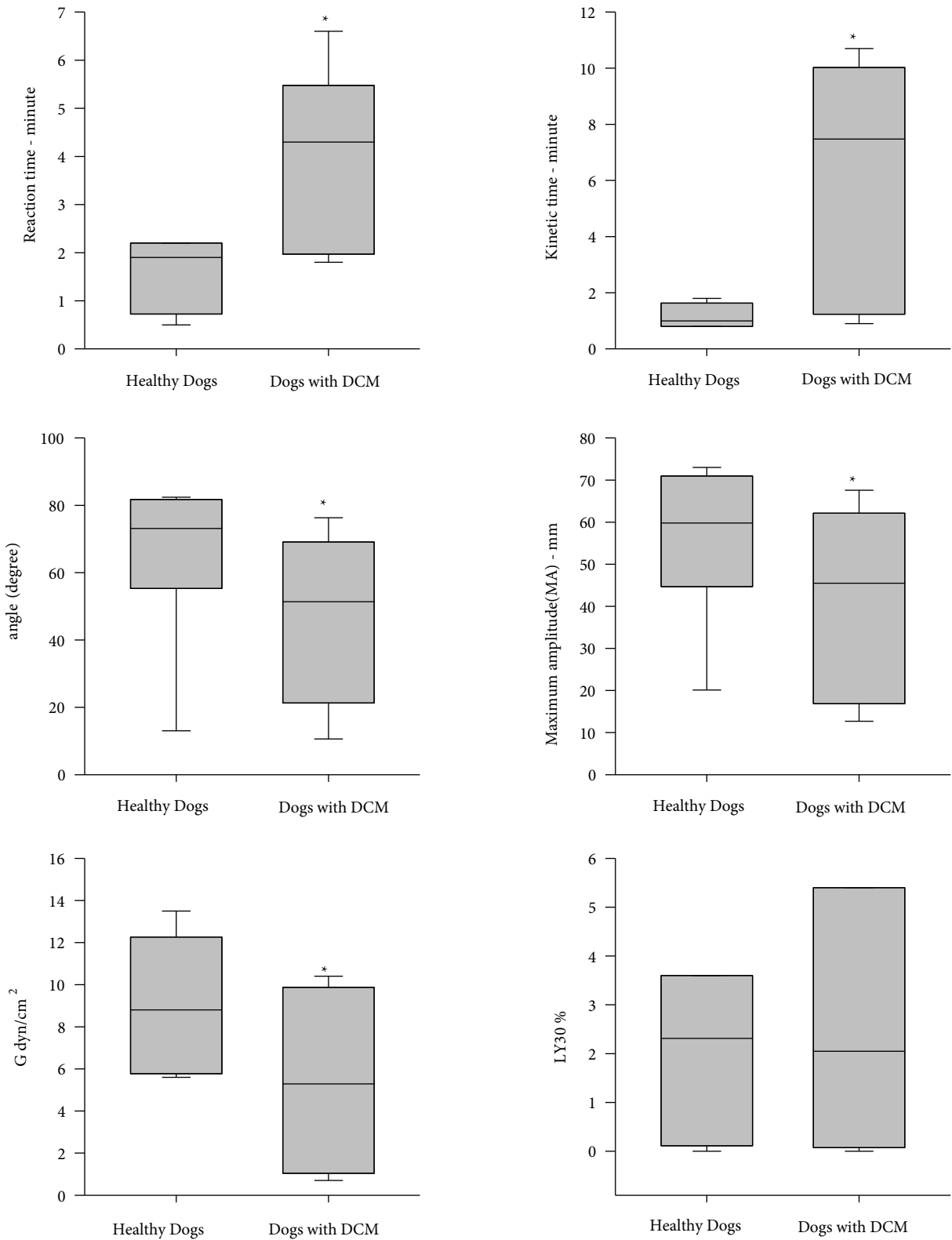


Figure 2. Comparison of reaction time (R), kinetic time (K), alpha angle, maximum amplitude (MA), G value, and LY30 between control (healthy) dogs and dogs with dilated cardiomyopathy (DCM). Data are presented as boxes and whiskers. Each box includes the interquartile range, whereas the line within a box represents the median; the whiskers represent the range and extend to a maximum of 1.5 times the interquartile range. *P < 0.05, as compared to healthy controls.

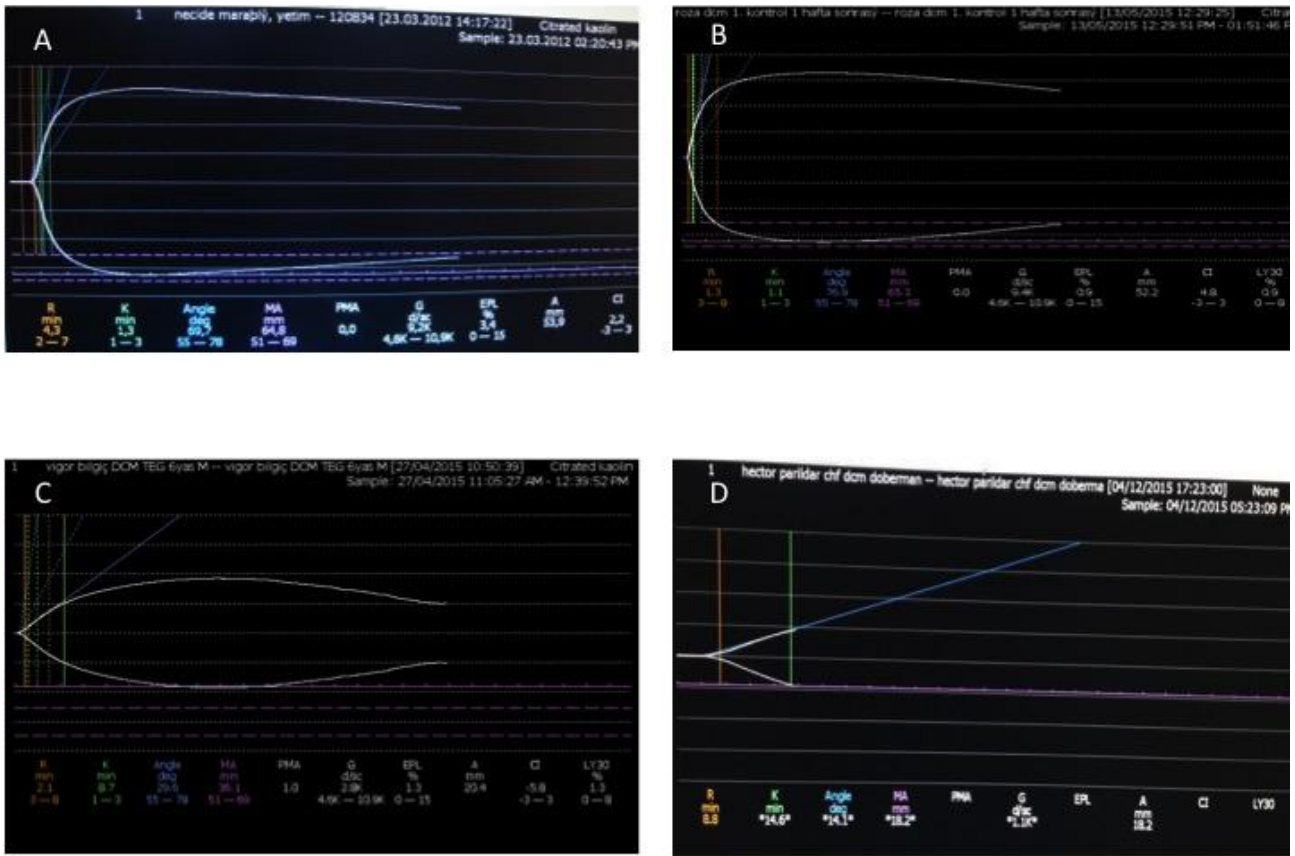


Figure 3. Some individual data of TEG profiles in dogs with dilated cardiomyopathy indicating normal coagulation (A), hypercoagulation due to shortened R and K times and increased MA and alpha angle (B), and hypocoagulation states or platelet dysfunction due to reduced MA and alpha angle (C and D).

Since PT and aPTT values are reported to have limited diagnostic accuracy for hypercoagulation, TEG has been suggested as an alternative diagnostic tool that has higher sensitivity and specificity to show hypercoagulation and hypocoagulation when compared to traditional coagulation assays (PT, aPTT, or d-dimer) (9,11). In the present study, the observed increase in mean R and K times, as well as decreased MA, α -angle, G, and CI values, as compared with the data of control dogs as shown in Figure 2, seem related to hypocoagulation (platelet dysfunction and secondary fibrinolysis) in dogs with DCM. The state of hypocoagulation may be related with platelet dysfunction rather than a decrease in serum proteins of coagulation and thrombocytopenia in dogs suffering from heart diseases. On the other hand, that there was no statistically significant change in LY30 (a TEG parameter indicating fibrinolysis) between groups did not support a hypocoagulation status in these patients. Therefore, further and more detailed studies are needed to confirm these observations in dogs with DCM.

Individual data of some dogs studied were consistent with the hypercoagulation state represented in Figure 3.

This observation is compatible with those of previous studies indicating the presence of hypercoagulation or a prothrombotic state during heart diseases in humans (7,18,22) and dogs (23). Previous studies reported hypercoagulable results based on TEG measurements in dogs with parvoviral enteritis (24), endotoxemia (11), neoplasia (25), and immune-mediated hemolytic anemia (26). A hypercoagulable state in dogs with DCM may be due to increased catecholamine and cytokine responses, upregulation of the renin-angiotensin-aldosterone system, or increased P-selection expression during heart failure (27-29).

In this study, myocardial damage was confirmed by observed increases in serum cTnI values, as compared to controls, like in previous studies (14-16). There is a lack of information on how the presence and severity of myocardial injury affects the coagulation status in patients with advanced heart diseases. The results of the Pearson correlations suggested that cTnI and TEG parameters did change independently in the course of heart disease in dogs. There was positive correlation between aPTT and R and K times, suggesting that aPTT value may represent

a quality of clot kinetics in addition to evaluation of the intrinsic and common pathways of coagulation (9).

In conclusion, the present study shows, for the first time according to TEG measurements, that individual results were commonly compatible with a hypercoagulation rather than hypocoagulation state in dogs with DCM. Clinicians should keep in mind that coagulation status

is a dynamic process and might change to a hyper- or hypocoagulation state in dogs with DCM, regardless of myocardial injury. Thrombolytic therapy in patients with a hypocoagulation state due to heart problems would be contraindicated. Thus, TEG evaluation may be necessary before treatment to determine the trend of coagulation in canine veterinary practice.

References

1. Wendy WA. Cardiovascular Disease in Small Animal Medicine. 3rd ed. London, UK: Manson Publishing; 2011.
2. Martin MW, Stafford Johnson MJ, Strehlau G, King JN. Canine dilated cardiomyopathy: a retrospective study of prognostic findings in 367 clinical cases. *J Small Anim Pract* 2010; 8: 428-436.
3. Oyama MA. Canine cardiomyopathy. In: Smith F, Tilley L, Oyama M, Sleeper M, editors. *Manual of Canine and Feline Cardiology*. 5th ed. St. Louis, MO, USA: Elsevier; 2016. pp. 141-152.
4. Dukes-McEwan J, Borgarelli M, Tidholm A, Vollmar AC, Häggström J. Proposed guidelines for the diagnosis of canine idiopathic dilated cardiomyopathy. *Journal of Veterinary Cardiology* 2003; 5: 7-19.
5. Maron BJ, Towbin JA, Thiene G, Antzelevitch C, Corrado D, Arnett D, Moss AJ, Seidman CE, Young JB. Contemporary definitions and classification of the cardiomyopathies. *Circulation* 2006; 113: 1807-1816.
6. Sbarouni E, Bradshaw A, Andreotti F, Tuddenham E, Oakley CM, Cleland JG. Relationship between hemostatic abnormalities and neuroendocrine activity in heart failure. *Am Heart J* 1994; 127: 607-612.
7. De Lorenzo F, Saba N, Kakkar VV. Blood coagulation in patients with chronic heart failure: evidence for hypercoagulable state and potential for pharmacological intervention. *Drugs* 2003; 63: 565-576.
8. Tarnow I, Falk T, Tidholm A, Martinussen T, Jensen AL, Olsen LH, Pedersen HD, Kristensen AT. Hemostatic biomarkers in dogs with chronic congestive heart failure. *J Vet Intern Med* 2007; 21: 451-457.
9. Lubas G, Caldin M, Wiinber B, Kristensen AT. Laboratory Testing of Coagulation Disorders. In: Weiss DJ, Wardrop KJ, editors. *Schalm's Veterinary Hematology*. 6th ed. Ames, IA, USA: Wiley-Blackwell; 2010. pp. 1082-1100.
10. Bauer N, Eralp O, Moritz A. Establishment of reference intervals for kaolin-activated thromboelastography in dogs including an assessment of the effects of sex and anticoagulant use. *J Vet Diagn Invest* 2009; 21: 641-648.
11. Eralp O, Yilmaz Z, Failing K, Moritz A, Bauer N. Effect of experimental endotoxemia on thromboelastography parameters, secondary and tertiary hemostasis in dogs. *J Vet Int Med* 2011; 25: 524-531.
12. Kocatürk M, Eralp İnan O, Levent P, Yılmaz Z. Protective effects of S-adenosylmethionine (SAME) and silybin on hepatorenal and hemostatic functions in dogs with endotoxemia. *Turk J Vet Anim Sci* 2016; 40: 788-796.
13. Eralp İnan O, Kocatürk M, Mecitoğlu Z, Yılmaz Z. Thromboelastographic evaluation of coagulation in a dog with anticoagulant rodenticide intoxication. *Kafkas Univ Vet Fak* 2016; 22: 477-478.
14. Oyama MA. Using cardiac biomarkers in veterinary practice. *Vet Clin North Am Small Anim Pract* 2013; 43: 1261-1272.
15. Çakıroğlu D, Meral Y, Bakirel U, Kazancı D. Cardiac troponin levels in dogs with dilate cardiomyopathy. *Kafkas Univ Vet Fak* 2009; 15: 13-17.
16. Güneş V, Uyanık F, Eren M, Kibar M, Aslan Ö, Onmaz AC. The rapid analyses of cardiac troponins in dogs with dilated cardiomyopathy, distemper or parvovirus infection. *Kafkas Univ Vet Fak* 2014; 20: 921-927.
17. Wendy WA. Cardiovascular system disorders. In: Nelson RW, Couto CG, editors. *Small Animal Internal Medicine*. 5th ed. St. Louis, MO, USA: Elsevier; 2013. pp. 130-158.
18. Boon JA. *Veterinary Echocardiography*. 2nd ed. Ames, IA, USA: Wiley-Blackwell; 2010.
19. Mongirdiene A, Kursvietiene L, Kasauskas A. The coagulation system changes in patients with chronic heart failure. *Medicina (Kaunas)* 2010; 46: 642-647.
20. Tarnow I, Kristensen AT, Olsen LH, Pedersen HD. Assessment of changes in hemostatic markers in Cavalier King Charles Spaniels with myxomatous mitral valve disease. *Am J Vet Res* 2004; 65: 1644-1652.
21. Bédard C, Lanevski-Pietersma A, Dunn M. Evaluation of coagulation markers in the plasma of healthy cats and cats with asymptomatic hypertrophic cardiomyopathy. *Vet Clin Pathol* 2007; 36: 167-172.
22. Davis CJ, Gurbel PA, Gattis WA, Fuzaylov SY, Nair GV, O'Connor CM, Serebruany VL. Hemostatic abnormalities in patients with congestive heart failure: diagnostic significance and clinical challenge. *Int J Cardiol* 2000; 75: 15-21.
23. Prihirunkit K, Sastravaha A, Lekcharoensuk C, Chanloinapha P. Hemostatic markers in congestive heart failure dogs with mitral valve disease. *Journal of Veterinary Medicine* 2014; 2014: 589873.

24. Otto CM, Rieser TM, Brooks MB, Russell MW. Evidence of hypercoagulability in dogs with parvoviral enteritis. *J Am Vet Med Assoc* 2000; 217: 1500-1504.
25. Kristensen AT, Wiinberg B, Jessen LR, Adreasen E, Jensen AL. Evaluation of human recombinant tissue factor-activated thromboelastography in 49 dogs with neoplasia. *J Vet Intern Med* 2008; 22: 140-147.
26. Sinnott VB, Otto CM. Use of thromboelastography in dogs with immune- mediated hemolytic anemia: 39 cases (2000–2008). *J Vet Emerg Crit Care* 2009; 19: 484-488.
27. Chung I, Lip GY. Platelets and heart failure. *Eur Heart J* 2006; 27: 2623-2631.
28. Tarnow I, Andreasen SHS, Olsen LH, Moesgaard SG, Rasmussen CE, Kristensen AT, Falk BT. Congestive heart failure in dogs is associated with enhanced platelet-leukocyte aggregates - a marker for platelet activation. *J of Vet Int Med* 2010; 24: 673-673.
29. Tarnow I, Kristensen A, Olsen LH, Falk T, Haubro L, Pedersen LG, Pedersen HD. Dogs with heart diseases causing turbulent high-velocity blood flow have changes in platelet function and von Willebrand factor multimer distribution. *J Vet Intern Med* 2005; 19: 515-522.