



ADAMTS4, 5, 9, and 15 Expressions in the Autopsied Brain of Patients with Alzheimer's Disease: A Preliminary Immunohistochemistry Study

Sultan Pehlivan, Prof. Recep Fedakar, Bulent Eren, Assist. Prof. Sumeyya Akyol, Filiz Eren, Assoc. Prof. Nursel Turkmen Inanir, Murat Serdar Gurses, Mustafa Numan Ural, Prof. Suleyman Murat Tagil & Assoc. Prof. Kadir Demircan

To cite this article: Sultan Pehlivan, Prof. Recep Fedakar, Bulent Eren, Assist. Prof. Sumeyya Akyol, Filiz Eren, Assoc. Prof. Nursel Turkmen Inanir, Murat Serdar Gurses, Mustafa Numan Ural, Prof. Suleyman Murat Tagil & Assoc. Prof. Kadir Demircan (2016) ADAMTS4, 5, 9, and 15 Expressions in the Autopsied Brain of Patients with Alzheimer's Disease: A Preliminary Immunohistochemistry Study, Klinik Psikofarmakoloji Bülteni-Bulletin of Clinical Psychopharmacology, 26:1, 7-14, DOI: [10.5455/bcp.20150706034008](https://doi.org/10.5455/bcp.20150706034008)

To link to this article: <https://doi.org/10.5455/bcp.20150706034008>



© 2016 Taylor and Francis Group, LLC



Published online: 08 Nov 2016.



Submit your article to this journal [↗](#)



Article views: 380



View related articles [↗](#)



View Crossmark data [↗](#)



Citing articles: 4 View citing articles [↗](#)

ADAMTS4, 5, 9, and 15 Expressions in the Autopsied Brain of Patients with Alzheimer's Disease: A Preliminary Immunohistochemistry Study

Sultan Pehlivan¹, Recep Fedakar², Bulent Eren³, Sumeyya Akyol⁴, Filiz Eren³, Nursel Turkmen Inanir⁵, Murat Serdar Gurses⁶, Mustafa Numan Ural⁶, Suleyman Murat Tagil⁷, Kadir Demircan⁸

ABSTRACT:

ADAMTS4, 5, 9, and 15 expressions in the autopsied brain of patients with Alzheimer's disease: a preliminary immunohistochemistry study

Objective: Recent studies performed in the central nervous system highlight the pathophysiological relevance of A disintegrin-like and metalloproteinase with thrombospondin motifs (ADAMTS) genes and their protein products. The determination of alterations in expression profiles of ADAMTS family genes in Alzheimer's disease (AD) patients may contribute to the explanation of tissue pathology and also new ideas for remedial approaches for this incurable but preventable disease. Therefore, the goal of this study was to describe and identify the distribution, characteristics, and any changes in the expression, in other words, immunoreactivity, for aggrecanases (ADAMTS4, 5, 9, and 15) proteins in AD brain.

Methods: Nine cases that were autopsied in the Council of Forensic Medicine, Bursa Morgue Department in 2013, were selected. All of the cases were sent for autopsy to the institution within 8 hours after death. At autopsy, tissue samples were obtained for histopathological examination of organs for determining the cause of death. Out of these, two cases were diagnosed with AD by neurologists when they were alive. Immunohistochemical staining was performed on the brain slides by using relevant primary and secondary antibodies against aggrecanase proteins. All images were acquired using a X200 objective of a microscope (Olympus BX53) and evaluated by the staining intensity using a semi-quantitative scoring system.

Results: ADAMTS4 and 5 were slightly under-expressed in the brains from autopsied AD cases compared to those of control brains and suggested that extracellular matrix (ECM) degradation was not endorsed in AD brain. On the other hand, ADAMTS9 and 15 aggrecanases were not found to be expressed in correspondent brain sections of AD and control cases.

Conclusion: The current study demonstrated that some aggrecanases were found to be under-expressed in AD brains. Additional studies in which all ADAMTS enzymes will be studied in terms of mRNA and protein levels are needed to understand the relative contributions of ADAMTS genes and proteins in AD brains.

Keywords: Aggrecanases, Alzheimer's disease, ADAMTS4, ADAMTS5, ADAMTS9, ADAMTS15

Klinik Psikofarmakoloji Bulteni - Bulletin of Clinical Psychopharmacology 2016;26(1):7-14



¹M.D., Ankara Regional Office of Council of Forensic Medicine, Morgue Department, Ankara - Turkey
²Prof., ³Assoc. Prof., ⁴M.D., Uludag University, Medical Faculty, Department of Forensic Medicine, Bursa - Turkey
⁵M.D., Bursa Regional Office of Council of Forensic Medicine, Morgue Department, Bursa - Turkey
⁶PhD., Assist. Prof., ⁸Assoc. Prof., Turgut Ozal University, Medical Faculty, Department of Medical Biology, Ankara - Turkey
⁷Prof., Turgut Ozal University, Medical Faculty, Department of Anatomy, Ankara - Turkey

Corresponding author:

Dr. Sultan Pehlivan,
Adli Tip Kurumu Ankara Grup Başkanlığı,
Morg Departmanı, Patoloji Bölümü,
Sevkat Mahallesi, Dr. Besim Ömer Caddesi
No: 45, Keçiören, Ankara - Türkiye

Phone: +90-312-340-0073

Fax: +90-312-340-6629

E-mail address:
drspehlivan@hotmail.com

Date of submission:
December 31, 2014

Date of acceptance:
July 06, 2015

Declaration of interest:

S.P., R.F., B.E., S.A., F.E., N.T.I., M.S.G., M.N.U., S.M.T., K.D.: The authors reported no conflicts of interest related to this article.

INTRODUCTION

Alzheimer's disease (AD) is a progressive multifactorial neurodegenerative disorder with a progression for 20-30 years before clinical onset¹. Amyloid plaques are one of the pathological

hallmarks of AD and amyloid β (A β) peptide was found to have a crucial role in the pathophysiology of AD. Greater numbers of patients do not have an elevated A β production of amyloid protein precursor overexpression in the brain. The pathophysiological processes that underlie this

disorder are not completely understood. However, an expanding body of data indicates that matrix metalloproteinases (MMP) might play an essential role in the pathophysiology of AD. When the numbers of senile plaques in the hippocampus and parietal cortex were compared each other after stained with anti-MMP-3 antibodies, it was noticed that fewer plaques were stained in the hippocampus area. The discriminatory dissemination of MMP-3 in the brain offers that MMP-3 might play a critical role in the pathophysiology of AD, notably in the deterioration of A β protein².

As an important proteoglycan of cartilage, aggrecan is responsible for its durability and flexibility. In the structure, aggrecan, the core protein, covalently binds to hyaluronic acid, glycosaminoglycans, and link proteins to build up huge aggregates, assembling components of the extracellular matrix (ECM). This compound is also allocated in all parts of the brain³. ECM in the CNS is deposited in the ECM of the neuropil (the fibrous network of nervous tissue that forms the gray matter) and neighboring a subgroup of neurons in the pattern of unique perineuronal nets, coverings of ECM that perikarya unsheathed, proximal dendrites, and axon initial segments.

Unlike ADAMs protease enzymes that are mostly transmembrane proteins, the A disintegrin-like and metalloproteinase with thrombospondin motifs (ADAMTS) proteins have been known as secreted protease enzymes, some of which can bind to the ECM. The functions of ECM binding, substrate recognition, and degradation are moderated by means of the central and C-terminal TS repeats and the spacer region^{4,5}. After numerous comprehensive studies, ADAMTS expression has been found in the CNS^{4,6,7} and is known to be changed in disease conditions⁸⁻¹⁰. The class aggrecanases of MMP have been known to have members ADAMTS 4, 5, 9, and 15. These aggrecanases are responsible for breaking down at the Glu373-Ala 374 bond of aggrecan protein as well as partly versican and brevican degradation. Atypical gathering of possible substrates for ADAMTS1 and 5 has been detected in senile plaques of AD⁸. It was addressed that

chondroitin-4 sulfate was found both in neurofibrillary tangles and senile plaques in AD and chondroitin-6 sulfate in the area around senile plaques and neurofibrillary tangles¹¹. In another study¹², this was criticized and suggested a role of various glycosaminoglycans containing chondroitin sulfate for favoring A β polymerization *in vitro* and *in vivo*. Definitely, heparin and chondroitin sulfate proteoglycans were addressed to confine at sites of A β deposition in different parts of brain of patients with AD^{13,14} and the elevation of enzymes that degrade proteoglycans might be a mechanism to cancel out excess A β deposition and polymerization in AD as well as other neurodegenerative disorders¹².

A β accumulation in the CNS is attributed to the cause or consequence of the loss of blood brain barrier (BBB) function in AD. Nonetheless, other A β -independent pathologies can phenotypically imitate BBB dysfunction noticed in AD, and a lot of alterations in the BBB can cause neurotoxicity independently of A β ¹⁵. On the other hand, it has been suggested that the pathophysiology of AD should include inflammatory element(s). AD progression has several significant factors such as activity of inflammatory cells and the elaboration of harmful molecules by responsible cells. In peripheral inflammatory conditions, the elevated MMP activities are major causes of tissue degradation and further deterioration in some diseases such as rheumatoid arthritis. MMP-1 levels were found to be significantly increased by almost 50% in all cortical areas of AD. It is, therefore, possible that MMP-1 activity in AD may contribute to the BBB dysfunction occurred in AD¹⁶. It is also a possibility that the degradation products of aggrecanases may lead the activation of inflammatory cells that results in BBB dysfunction.

Little information is available on the ADAMTS expression in AD brain although it has been discovered experimentally that their expression level may be regulated by several mediators in a cell type-specific manner¹⁷⁻²⁰. Considering that recent studies performed in the CNS highlight the pathophysiological relevance of ADAMTS gene, the determination of alterations in expression

profiles of ADAMTS family genes in AD patients may contribute to the explanation of tissue pathology and also new ideas for remedial approaches for this incurable but preventable disease. Thus, the goal of the present study was to identify and describe the characteristics, distribution, and any changes in the expression, in other words, immunoreactivity for ADAMTS proteins/ enzymes in AD brain.

MATERIALS AND METHODS

Nine cases that were autopsied in the Council of Forensic Medicine, Bursa Morgue Department in 2013, were selected. All of the cases were sent for autopsy to our institution within 8 hours following death. The details of all cases were shown in Table 1. Two patients were diagnosed with AD, and one patient without AD from each following age groups 25-35, 36-45, 46-55, 56-65, 66-75, 76-85, and >85 were included as control. The medical records of the cases were retrospectively reviewed. Diagnosis of AD was based on the criteria of the National Institute of Neurological and Communicative Disorders and Stroke and AD and Related Disorders Association (NINCDS-ADRDA)^{21,22}. These criteria were also used for the exclusion of neurocognitive disorders. Controls

had to be free of neurological or psychiatric diseases. The Turkish version of the Mini Mental State Examination (MMSE) was used for cognitive assessments of AD patients by neurologists. Geriatric depression scale (GDS) was used and brain imaging with magnetic resonance was also performed for these patients at the time of diagnosis.

At autopsy, tissue samples were taken for histopathological examination of organs for determining the cause of death. All nine cases (AD patients and controls) were examined for the cause of death, and brain macroscopic and microscopic findings in detail. Tissue samples were taken from temporal brain regions in each case and were fixed in formalin (10%) and embedded in paraffin wax. Sections of 3-4 µm thicknesses were cut and stained by using hematoxylin and eosin. Ethical permissions for this study were taken from local Ethical Committee (Bursa) and Ethical Committee of Council of Forensic Medicine (Istanbul).

Immunohistochemistry

The samples were embedded in paraffin blocks following the fixation procedure by using 10% formaldehyde and 5 µm-thickness sections were

Table 1: Descriptive characteristics of the cases (age, gender, cause of death, cerebral macroscopic and microscopic findings), staining extensity/ intensity scores of ADAMTS4, 5, 9, and 15.

Cases	Age	Gender	Cause of death	Histopathologic findings of the brain	Macroscopic findings of the brain	ADAMTS4		ADAMTS5		ADAMTS9		ADAMTS15	
						EXT	INT	EXT	INT	EXT	INT	EXT	INT
AD Case 1	66	Female	Undetermined	Congestion	Normal	1	1	2	2	0	0	0	0
AD Case 2	59	Female	Heart failure	Congestion	Normal	2	1	2	1	1	1	0	0
Case 3	30	Male	Other causes of internal	Congestion	Normal	1	1	4	2	0	0	0	0
Case 4	41	Male	Traumatic brain hemorrhage	Subarachnoid hemorrhage and subcortical hemorrhage	Subarachnoid hemorrhage and brain contusion	1	1	2	1	0	0	0	0
Case 5	53	Male	Manual strangulation	Normal	Atherosclerotic changes in the basilar artery	1	1	1	1	0	0	0	0
Case 6	56	Male	Coronary artery disease	Congestion	Normal	2	1	4	2	0	0	0	0
Case 7	66	Male	Heart failure	Normal	Atherosclerotic changes in the cerebral arteries	3	2	4	1	0	0	0	0
Case 8	79	Male	Heart failure	Congestion	Atherosclerotic changes in the cerebral arteries	3	2	3	2	0	0	0	0
Case 9	87	Male	Thrombus in the coronary artery	Congestion	Atherosclerotic changes in the cerebral arteries (Circle of Willis)	3	1	2	1	0	0	1	1

AD: Alzheimer's disease, EXT: extensity, INT: intensity

gathered from the preferred paraffin blocks and were taken on APTES-coated slides. By using xylene and graded alcohol, the sections were sequentially deparaffinized and rehydrated. Following rehydration procedure, sections were subjected to 2% hydrogen peroxide (H₂O₂) and methanol for 5 min to avoid intrinsic peroxidase activity and its undesired effects. Samples were washed 3 times with phosphate-buffered saline (PBS) (pH: 7.4), and warmed in a microwave oven within 0.1 nM sodium citrate for 10 min. By doing the last treatment, the antigen retrieval procedure was completed. Following sequential procedures of incubation and blocking of the non-immune serum at room temperature (20 min), the sections taken on polylysine lams were performed by immunohistochemical method by using anti-ADAMTS4, anti-ADAMTS5, anti-ADAMST9, and anti-ADAMTS15 antibodies. The procedures were proceeded according to the protocols approved for anti-ADAMTS4, anti-ADAMTS5, anti-ADAMST9, and anti-ADAMTS15 antibodies (Abcam). After being deparaffinized at 65°C in heat chamber and rehydrated, sections were subjected epitope retrieval in 10X EDTA buffer (pH 8.0) in 110 °C for 30 min. Subsequently, the sections were subjected exposure of 3% H₂O₂ for 20 min to bleach endogenous peroxidases, followed by rinsing 3 times within PBS (10 min). The obtained sections were respectively incubated with an anti-ADAMTS4 (ab84792), anti-ADAMTS5 (ab41037), anti-ADAMST9 (ab28279), and anti-human ADAMTS15 (ab28516) (all 1:250 in BSA) for 1 h at 37°C, washed 3 times in PBS and incubated in a biotinylated goat secondary anti-mouse polyclonal antibody (ab80436) for 15 min at 37°C. The omission procedure of primary antibodies was used to examine the specificity of the antibodies. Following washing with PBS, the tissue sections were visualized by using 3,3'-diaminobenzidine tetrahydrochloride (DAB chromogen, Abcam) and counterstained with hematoxylin. Lastly, the sections were dehydrated in graded ethanol, immersed in xylene and coverslipped. All images were acquired using a 200X objective and a microscope (Olympus BX53).

Statistical Methods

Regarding extensity, the staining scores were determined for all sections: 0, if it exhibited no staining; 1 (1-25%), occasional staining with most fields negative; 2 (26-50%), focally abundant staining with most fields having no staining; 3 (51-75%), focally abundant staining with most fields showing positive staining; or 4 (76-100%), prominent staining throughout the section. The staining intensity was recorded using a semi-quantitative scoring system: 0: absent; 1: weak staining; 2: accumulations with greater staining intensity; 3: strong and dark staining; 4: very strong and, the darkest observed staining.

RESULTS

All specimens were stained by immunohistochemical methods, and staining scores were determined. ADAMTS4 and 5 immunoreactivity were consistently demonstrated in tissue sections of normal and AD cases. ADAMTS4 and 5 immunostaining were heterogeneous in its distribution between sections. The extensity and intensity values for ADAMTS9 and 15 were negative for the brain sections from AD and control cases. It presumably shows that ADAMTS9 and 15 have not been expressed in the correspondent brain sections. Descriptive characteristics of all cases, extensity, and intensity of immunohistochemical staining patterns were summarized in Table 1. Median age of the 7 male and 2 female patients was 59.6 years (min. 30, and max. 87 years). Causes of death of the patients included other causes of internal (n=2), manual strangulation (n=1), coronary artery disease (n=1), brain hemorrhage due to head trauma (n=1), heart failure (n=3), and thrombus in the coronary artery (n=1). Median distribution (extensity) scores of immunohistochemical staining were estimated as 1.9 for ADAMTS4 and 2.7 for ADAMTS5 (as shown in Figures 1 and 2), whereas 0.11 for both ADAMTS9 and 15 (as shown in Figure 3 and 4). Intensity scores were also

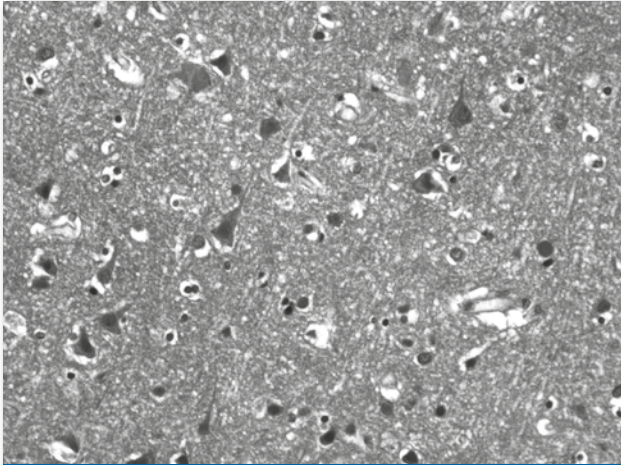


Figure 1: ADAMTS4 immunostaining in postmortem brain tissue. Strong staining for ADAMTS4 can be detected in the neuron cells, glial cells, and neuropil (original magnification, ×200).

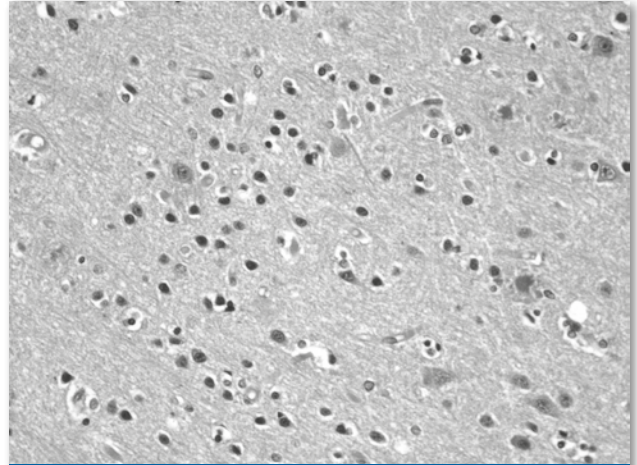


Figure 3: ADAMTS9 immunostaining in postmortem brain tissue. It shows focal immunostaining for ADAMTS9 of the glial cells, most likely astrocytes (original magnification, ×200).

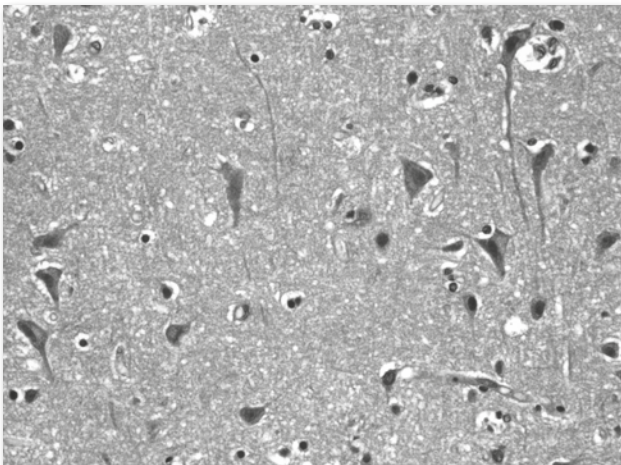


Figure 2: ADAMTS5 immunostaining in postmortem brain tissue. Diffuse strongly expression of ADAMTS5 was noted (original magnification, ×200).

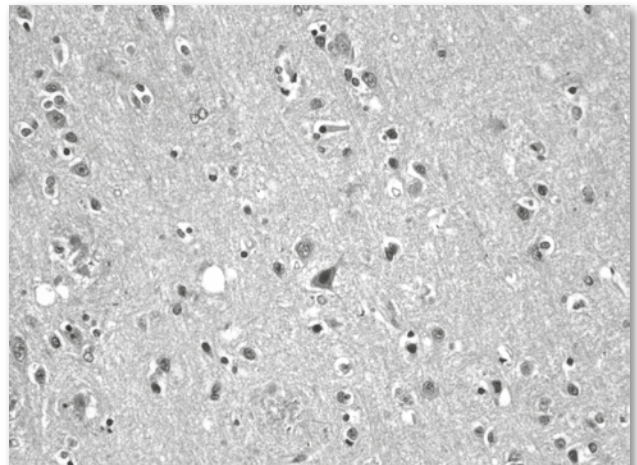


Figure 4: ADAMTS15 immunostaining in postmortem brain tissue. No staining was observed in neuron cells and glial cells with ADAMTS15 (original magnification, ×200).

estimated as 1.2 for ADAMTS 4, 1.4 for ADAMTS5, 0.11 for both ADAMTS9 and 15 for respective histochemical markers.

ADAMTS4 and 5 were relatively slightly higher compared to ADAMTS9 and 15. Furthermore, the extensity and intensity of staining were more significant in those cases with cerebral atherosclerosis compared to AD cases. In AD cases, the extensity was 1-2 and intensity was 1-1 for ADAMTS4, while the extensity was 3-3-3 and intensity was 2-2-1 for atherosclerotic cases. For ADAMTS5, the extensity was 2-2 and intensity was

2-1 in AD cases, while its extensity was 4-3-2 and intensity was 1-2-1 for atherosclerotic cases. These findings indicate that the extensity and intensity of staining are more significant and scores are higher in cases with atherosclerosis, heart failure or coronary artery disease.

On the other hand, in a case with traumatic brain hemorrhage, immunohistochemical staining scores were 1-1 and 1-2 for ADAMTS4 and 5, respectively. These staining scores were also lower than those detected in cases with heart disease.

DISCUSSION

There is a debate in the literature about the increasing/decreasing immunoreactivity in AD brain in terms of some aggrecanases. The present study demonstrated that ADAMTS4 and 5 were slightly under-expressed in the brains from autopsied AD patients compared to those of control brains and implied that ECM deterioration was not boosted in the brains of patients with AD. On the other hand, ADAMTS9 and 15 aggrecanases were not found to be expressed in correspondent brain sections of AD and control cases.

In our cases with AD, distribution scores of immunohistochemical staining for ADAMTS4 (1 vs 2), ADAMTS5 (2 vs 2), ADAMTS9 (0 vs 1), and ADAMTS15 (0 vs 0) were detected as indicated in parentheses. The lowest and the highest mean staining intensity scores belonged to ADAMTS4 and ADAMTS5 were detected as 1.2 and 1.4, respectively. The lowest mean distribution (extensity) score was detected as 0.11 for ADAMTS9 and ADAMTS15, while the highest score 2.6 belonged to ADAMTS5. The lowest and the highest intensity scores belonged to ADAMTS9 and 15 were 0.11, and ADAMTS5 was 1.4, respectively.

As in lots of structures in human brain, the steady levels of A β are identified by the equilibrium of their generation and elimination velocities. Dysfunction in A β elimination is essential for the accumulation of A β in the brains of AD patients. In the present study, it was explored and focused on the problems with respect to A β elimination mechanisms for the development of therapeutics targeting A β .

ADAMTS4, 5, 9 and 15 are within the glutamyl endopeptidase subgroup of ADAMTSs²³. The essential substrates of the mentioned peptidase enzymes are the aggregating chondroitin sulphate proteoglycans (CSPGs), including brevican, versican, and aggrecan, which are known to be the total integral components of ECM of the CNS^{24,25}. The CSPGs are expressed in the brain²⁵⁻²⁷ and known as possible substrates for ADAMTSs. These CSPGs are important to brain structure through maintenance of the correct hydrodynamics and in their interactions with other ECM components.

They also contribute to disease processes, and their synthesis is modulated by any kind of injuries²⁸. In normal physiological conditions, the ECM of the brain is a dynamic structure, which undergoes constant remodeling by processing of CSPGs²⁹. It has been reported that CSPGs (brevican, neurocan, phosphacan, versican, and NG2) are upregulated after CNS is subjected to any kind of injury³⁰⁻³³. We demonstrated here that ADAMTS4 and 5 expression were also slightly under-expressed in case of AD which indicated the inadequate degradation of ECM in these patients which in turn finally resulted in the accumulation of undesired ECM compounds by the time-course.

Injuries to the CNS such as trauma and stroke have been known to lead to a reactive gliosis characterized by increased glial fibrillary acidic protein (GFAP) expression and hypertrophy of astrocytes³⁴. Similarly, amyloid plaques are encircled by reactive astrocytes with an elevated expression of intermediate filaments such as GFAP in AD³⁵. It was proposed that GFAP and antibodies in CSF might have been used as a marker for severe neurodegeneration in AD and related/unrelated other CNS diseases³⁶. This was coexisted with changes in many brain ECM constituents including an increase in CSPGs³⁷. CSPGs are degraded specifically by ADAMTS and an elevated deterioration of ECM constituents might aid recovery by elimination of the CPGs that are inhibitory to neurite outgrowth. On the contrary, elevated ADAMTS-mediated CSPG elimination may enhance brain injury and capacitate infiltration of inflammatory cells^{28,38}.

Ajmo et al. described the allocation and characteristic immunoreactivity for the ADAMTS-directed cleavage of brevican, and compare this with Wisteria floribunda agglutinin (WFA) binding in the rodent CNS³⁹. They noticed a considerable discordance between the two, with the great width of distribution of the ADAMTS-derived brevican fragment being much expansive than that of WFA reactivity, which was an ordinary reagent needed to identify perineuronal nets of undamaged ECM and a marker which was thought to be a hallmark for regions of relative neural stability.

There are some limitations of our study that should be considered. First, the findings of this study are results of two cases, and second, both dementia cases were women while all comparison patients were men. Lack of adequate cases and unequal gender distribution should be managed by doing further studies to reach definitive conclusions with higher statistical power.

In spite of limited number of autopsies performed in AD disease cases, we think that our pilot study will make powerful contributions to the current

literature, encouraging new therapy modalities and new early diagnostic approaches. Additional studies in which all ADAMTS proteins will be studied in terms of mRNA and protein levels are needed to understand the relative contributions of ADAMTS in AD brains. Since, we need to define the functions of ADAMTS in both normal CNS physiology and in AD pathophysiology. Further illumination of the complexities of the ADAMTS proteinase system is needed to develop novel therapeutics for AD in addition to the classical therapy regimens.

References:

- Davies L, Wolska B, Hilbich C, Multhaup G, Martins R, Simms G, et al. A4 amyloid protein deposition and the diagnosis of Alzheimer's disease: prevalence in aged brains determined by immunocytochemistry compared with conventional neuropathologic techniques. *Neurology* 1988;38(11):1688-93. [\[CrossRef\]](#)
- Yoshiyama Y, Asahina M, Hattori T. Selective distribution of matrix metalloproteinase-3 (MMP-3) in Alzheimer's disease brain. *Acta Neuropathol* 2000;99(2):91-5. [\[CrossRef\]](#)
- Schwartz NB, Domowicz M, Krueger RC Jr, Li H, Mangoura D. Brain aggrecan. *Perspect Dev Neurobiol* 1996;3(4):291-306.
- Kuno K, Matsushima K. ADAMTS-1 protein anchors at the extracellular matrix through the thrombospondin type I motifs and its spacing region. *J Biol Chem* 1998;273(22):13912-7. [\[CrossRef\]](#)
- Tortorella M, Pratta M, Liu RQ, Abbaszade I, Ross H, Burn T, et al. The thrombospondin motif of aggrecanase-1 (ADAMTS-4) is critical for aggrecan substrate recognition and cleavage. *J Biol Chem* 2000;275(33):25791-7. [\[CrossRef\]](#)
- Abbaszade I, Liu RQ, Yang F, Rosenfeld SA, Ross OH, Link JR, et al. Cloning and characterization of ADAMTS11, an aggrecanase from the ADAMTS family. *J Biol Chem* 1999;274(33):23443-50. [\[CrossRef\]](#)
- Satoh K, Suzuki N, Yokota H. ADAMTS-4 (a disintegrin and metalloproteinase with thrombospondin motifs) is transcriptionally induced in beta-amyloid treated rat astrocytes. *Neurosci Lett* 2000;289(3):177-80. [\[CrossRef\]](#)
- Miguel RF, Pollak A, Lubec G. Metalloproteinase ADAMTS-1 but not ADAMTS-5 is manifold overexpressed in neurodegenerative disorders as Down syndrome, Alzheimer's and Pick's disease. *Brain Res Mol Brain Res* 2005;133(1):1-5. [\[CrossRef\]](#)
- Haddock G, Cross AK, Plumb J, Surr J, Buttler DJ, Bunning RA, et al. Expression of ADAMTS-1, -4, -5 and TIMP-3 in normal and multiple sclerosis CNS white matter. *Mult Scler* 2006;12(4):386-96. [\[CrossRef\]](#)
- Medina-Flores R, Wang G, Bissel SJ, Murphey-Corb M, Wiley CA. Destruction of extracellular matrix proteoglycans is pervasive in simian retroviral neuroinfection. *Neurobiol Dis* 2004;16(3):604-16. [\[CrossRef\]](#)
- DeWitt DA, Silver J, Canning DR, Perry G. Chondroitin sulfate proteoglycans are associated with the lesions of Alzheimer's disease. *Exp Neurol* 1993;121(2):149-52. [\[CrossRef\]](#)
- Diaz-Nido J, Wandosell F, Avila J. Glycosaminoglycans and beta-amyloid, prion and tau peptides in neurodegenerative diseases. *Peptides* 2002;23(7):1323-32. [\[CrossRef\]](#)
- Castillo GM, Lukito W, Wight TN, Snow AD. The sulfate moieties of glycosaminoglycans are critical for the enhancement of beta-amyloid protein fibril formation. *J Neurochem* 1999;72(4):1681-7. [\[CrossRef\]](#)
- Snow AD, Mar H, Nochlin D, Kimata K, Kato M, Suzuki S, et al. The presence of heparan sulfate proteoglycans in the neuritic plaques and congophilic angiopathy in Alzheimer's disease. *Am J Pathol* 1988;133(3):456-63.
- Erickson MA, Banks WA. Blood-brain barrier dysfunction as a cause and consequence of Alzheimer's disease. *J Cereb Blood Flow Metab* 2013;33(10):1500-13. [\[CrossRef\]](#)
- Corder EH, Saunders AM, Strittmatter WJ, Schmechel DE, Gaskell PC, Small GW, et al. Gene dose of apolipoprotein E type 4 allele and the risk of Alzheimer's disease in late onset families. *Science* 1993;261(5123):921-3. [\[CrossRef\]](#)
- Bevitt DJ, Mohamed J, Catterall JB, Li Z, Arris CE, Hiscott P, et al. Expression of ADAMTS metalloproteinases in the retinal pigment epithelium derived cell line ARPE-19: transcriptional regulation by TNFalpha. *Biochim Biophys Acta* 2003;1626(1-3):83-91. [\[CrossRef\]](#)
- Cross NA, Chandrasekharan S, Jokonya N, Fowles A, Hamdy FC, Buttler DJ, et al. The expression and regulation of ADAMTS-1, -4, -5, -9, and -15, and TIMP-3 by TGFbeta1 in prostate cells: relevance to the accumulation of versican. *Prostate* 2005;63(3):269-75. [\[CrossRef\]](#)

19. Tsuzaki M, Guyton G, Garrett W, Archambalut JM, Herzog W, Almekinders L, et al. IL-1 beta induces COX2, MMP-1, -3 and -13, ADAMTS-4, IL-1 beta and IL-6 in human tendon cells. *J Orthop Res* 2003;21(2):256-64. [\[CrossRef\]](#)
20. Yamanishi Y, Boyle DL, Clark M, Maki RA, Tortorella MD, Arner EC, et al. Expression and regulation of aggrecanase in arthritis: the role of TGF-beta. *J Immunol* 2002;168(3):1405-12. [\[CrossRef\]](#)
21. McKhann G, Drachman D, Folstein M, Katzman R, Price D, Stadlan EM. Clinical diagnosis of Alzheimer's disease: report of the NINCDS-ADRDA Work Group under the auspices of Department of Health and Human Services Task Force on Alzheimer's Disease. *Neurology* 1984;34(7):939-44. [\[CrossRef\]](#)
22. Khachaturian ZS. Diagnosis of Alzheimer's disease. *Arch Neurol* 1985;42(11):1097-105. [\[CrossRef\]](#)
23. Porter S, Clark IM, Kevorkian L, Edwards DR. The ADAMTS metalloproteinases. *Biochem J* 2005;386(Pt1):15-27. [\[CrossRef\]](#)
24. Galtrey CM, Fawcett JW. The role of chondroitin sulfate proteoglycans in regeneration and plasticity in the central nervous system. *Brain Res Rev* 2007;54(1):1-18. [\[CrossRef\]](#)
25. Yamaguchi Y. Lecticans: organizers of the brain extracellular matrix. *Cell Mol Life Sci* 2000;57(2):276-89. [\[CrossRef\]](#)
26. Inatani M, Honjo M, Otori Y, Oohira A, Kido N, Tano Y, et al. Inhibitory effects of neurocan and phosphacan on neurite outgrowth from retinal ganglion cells in culture. *Invest Ophthalmol Vis Sci* 2001;42(8):1930-8.
27. Novak U, Kaye AH. Extracellular matrix and the brain: components and function. *J Clin Neurosci* 2000;7(4):280-90. [\[CrossRef\]](#)
28. Jones LL, Margolis RU, Tuszynski MH. The chondroitin sulfate proteoglycans neurocan, brevican, phosphacan, and versican are differentially regulated following spinal cord injury. *Exp Neurol* 2003;182(2):399-411. [\[CrossRef\]](#)
29. Rauch U, Zhou XH, Roos G. Extracellular matrix alterations in brains lacking four of its components. *Biochem Biophys Res Commun* 2005;328(2):608-17. [\[CrossRef\]](#)
30. Friedlander DR, Milev P, Karthikeyan L, Margolis RK, Margolis RU, Grumet M. The neuronal chondroitin sulfate proteoglycan neurocan binds to the neural cell adhesion molecules Ng-CAM/L1/NILE and N-CAM, and inhibits neuronal adhesion and neurite outgrowth. *J Cell Biol* 1994;125(3):669-80. [\[CrossRef\]](#)
31. Yamada H, Watanabe K, Shimonaka M, Yamaguchi Y. Molecular cloning of brevican, a novel brain proteoglycan of the aggrecan/versican family. *J Biol Chem* 1994;269(13):10119-26.
32. Milev P, Friedlander DR, Sakurai T, Karthikeyan L, Flad M, Margolis RK, et al. Interactions of the chondroitin sulfate proteoglycan phosphacan, the extracellular domain of a receptor-type protein tyrosine phosphatase, with neurons, glia, and neural cell adhesion molecules. *J Cell Biol* 1994;127(6 Pt 1):1703-15. [\[CrossRef\]](#)
33. Schmalfeldt M, Bandtlow CE, Dours-Zimmermann MT, Winterhalter KH, Zimmermann DR. Brain derived versican V2 is a potent inhibitor of axonal growth. *J Cell Sci* 2000;113(Pt 5):807-16.
34. Pekny M, Nilsson M. Astrocyte activation and reactive gliosis. *Glia* 2005;50(4):427-34. [\[CrossRef\]](#)
35. Kamphuis W, Middeldorp J, Kooijman L, Sluijs JA, Kooi EJ, Moeton M, et al. Glial fibrillary acidic protein isoform expression in plaque related astrogliosis in Alzheimer's disease. *Neurobiol Aging* 2014;35(3):492-510. [\[CrossRef\]](#)
36. Teunissen CE, de Vente J, Steinbusch HW, De Bruijn C. Biochemical markers related to Alzheimer's dementia in serum and cerebrospinal fluid. *Neurobiol Aging* 2002;23(4):485-508. [\[CrossRef\]](#)
37. Smith GM, Strunz C. Growth factor and cytokine regulation of chondroitin sulfate proteoglycans by astrocytes. *Glia* 2005;52(3):209-18. [\[CrossRef\]](#)
38. Rhodes KE, Fawcett JW. Chondroitin sulphate proteoglycans: preventing plasticity or protecting the CNS? *J Anat* 2004;204(1):33-48. [\[CrossRef\]](#)
39. Ajmo JM, Eakin AK, Hamel MG, Gottschall PE. Discordant localization of WFA reactivity and brevican/ADAMTS-derived fragment in rodent brain. *BMC Neurosci* 2008;9:14. [\[CrossRef\]](#)