

1-1-2013

Epididymitis and orchitis caused by *Brucella melitensis* biovar 3 in a Merino ram

ESRA BÜYÜKCANGAZ

AYLİN ALASONYALILAR DEMİRER

SEVİL ERDENLİĞ

SABİRE DENİZ MISIRLIOĞLU

Follow this and additional works at: <https://journals.tubitak.gov.tr/veterinary>



Part of the [Animal Sciences Commons](#), and the [Veterinary Medicine Commons](#)

Recommended Citation

BÜYÜKCANGAZ, ESRA; DEMİRER, AYLİN ALASONYALILAR; ERDENLİĞ, SEVİL; and MISIRLIOĞLU, SABİRE DENİZ (2013) "Epididymitis and orchitis caused by *Brucella melitensis* biovar 3 in a Merino ram," *Turkish Journal of Veterinary & Animal Sciences*: Vol. 37: No. 3, Article 20. <https://doi.org/10.3906/vet-1201-25>
Available at: <https://journals.tubitak.gov.tr/veterinary/vol37/iss3/20>

This Article is brought to you for free and open access by TÜBİTAK Academic Journals. It has been accepted for inclusion in Turkish Journal of Veterinary & Animal Sciences by an authorized editor of TÜBİTAK Academic Journals. For more information, please contact academic.publications@tubitak.gov.tr.

Epididymitis and orchitis caused by *Brucella melitensis* biovar 3 in a Merino ram

Esra BÜYÜKCANGAZ^{1*}, Aylin ALASONYALILAR DEMİRER², Sevil ERDENLİĞ³, Sabire Deniz MISIRLIOĞLU²

¹Department of Microbiology, College of Veterinary Medicine, Uludağ University, 16059, Bursa, Turkey

²Department of Pathology, College of Veterinary Medicine, Uludağ University, 16059, Bursa, Turkey

³Pendik Veterinary Control and Research Institute, 34890 İstanbul, Turkey

Received: 19.01.2012 • Accepted: 25.07.2012 • Published Online: 03.06.2013 • Printed: 27.06.2013

Abstract: This paper describes a case of fibrinopurulent epididymitis and orchitis in a Merino ram owing to *Brucella melitensis* biovar 3, detected by histopathology, bacteriology, and PCR. Gross lesions included enlargement of the scrotum by abundant fibrinous exudate and adhesions between testicular tunics. Histopathologic lesions were characterized by epididymal abscesses and testicular atrophy. *B. melitensis* was cultured from the exudate as well as the internal organs of the ram. After conventional biotyping procedures were applied, the isolate was identified as *B. melitensis* biovar 3. The isolate was also confirmed as *Brucella* spp. by genus-specific PCR.

Key words: *Brucella melitensis* biovar 3, epididymitis, orchitis, ram

1. Introduction

Brucellosis is a leading cause of abortion, sterility, orchitis, arthritis, and hygromas in animals (1–3). The disease is considered to be highly endemic and causes zoonoses worldwide as reported by the World Organisation for Animal Health (4).

Orchitis in rams is generally associated with multiple bacterial agents (5,6) while epididymitis is mainly identified with *Brucella ovis*, which produces a non-zoonotic infection in sheep. On the other hand, *B. melitensis* is the main etiologic agent of small ruminant brucellosis and, as a highly virulent bacterium, plays a significant role in human brucellosis (1,3,4).

2. Case history

This report describes the pathological and microbiological characteristics of epididymitis and orchitis in a ram caused by *B. melitensis* biovar 3. A 1-year-old Merino ram with a history of chronic weight loss was referred for necropsy. A preliminary diagnosis of paratuberculosis was made based on the history and clinical signs.

The animal was euthanized and a necropsy was performed. On gross examination, the left testis was greatly enlarged (Figure 1a). The tunica vaginalis was thickened and adhesions were seen between the parietal and visceral layers. The tunic cavity was distended with approximately

360 mL of fibrinopurulent exudate. The left testis had a soft, pasty consistency. On cut surface the epididymis was characterized by foci of necrosis, multiple yellow fibrinopurulent foci (Figure 1b), and diffuse thickening and fibrinous adhesions of the testicular vaginal tunics. The right testis was atrophic, but normal in texture. Gross lesions of paratuberculosis were not observed in the animal.

Impression smears of tissues and fibrinous content taken from the right testis were stained with Gram and modified Ziehl-Neelsen methods, and organ specimens were collected for histopathological and microbiological examinations. A loop of exudate and tissue taken from aseptic cut surfaces of the organs (liver, lung, kidneys, and brain) were inoculated onto agar plates shown in the Table for routine microbiological diagnosis.

A Bru-Com Vet[®] (Secace Biotechnologies, Italy) commercial kit was used for molecular detection of the *Brucella* suspected isolate. All reagents were prepared at 22 °C and DNA extraction and the PCR conditions were carried out according to Buyukcangaz et al. (7). Ten microliters of amplicons and DNA molecular weight standards (Fermentas[®], USA) were loaded on 2% agarose gel in TAE using 0.6 µL/mL of ethidium bromide at 100 W for 75 min. The amplicons were visualized under UV light and photographed by MiniBIS Pro[®] (DNR's Bioimaging Systems, Israel).

* Correspondence: kocakaya@uludag.edu.tr

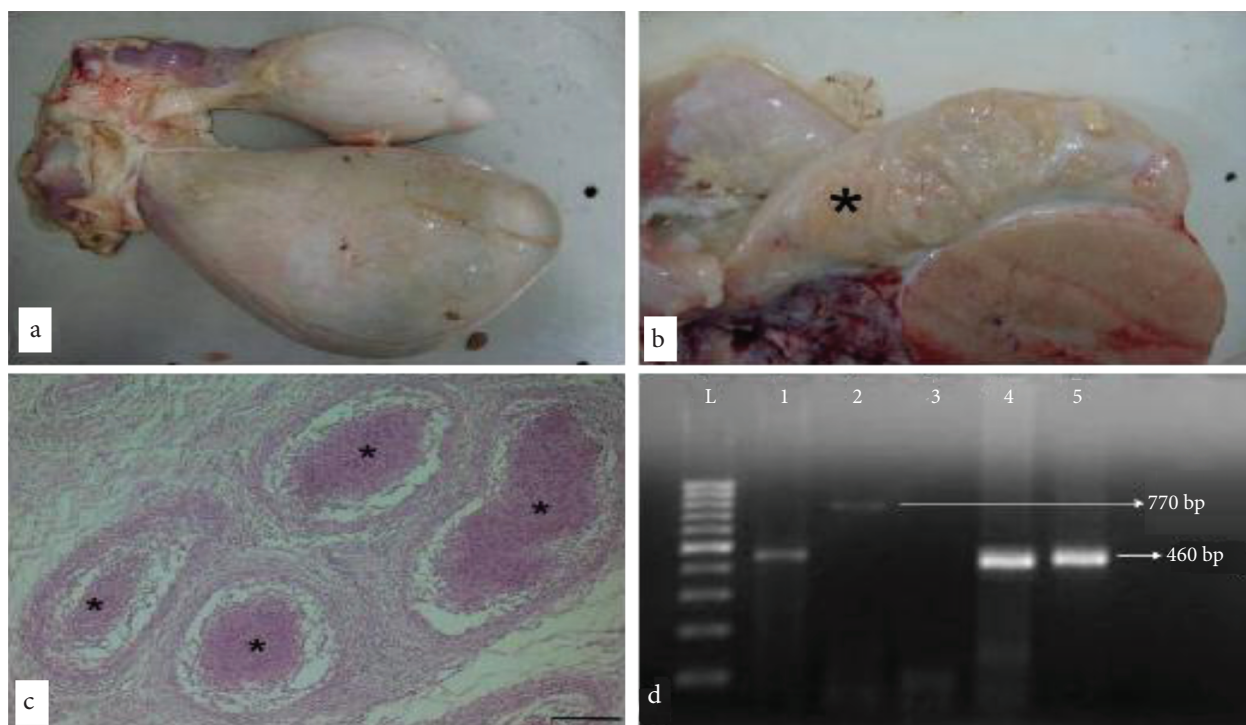


Figure 1. **a.** Enlargement of the left testis in comparison to the right testis of a ram with brucellosis. **b.** Testis from a ram infected with *Brucella melitensis* biovar 3 containing caseous abscesses (asterisk) of the epididymis. **c.** Necrotic efferent tubules (asterisks) and epididymitis, 4x, bar = 200 µm. **d.** *Brucella* PCR products obtained from isolate separated on a 1.5 % (w/v) agarose gel, L, Generuler™ 100 bp DNA Ladder Plus (SM0241; Fermentas), lane 1; Positive Cont. (+), lane 2; Negative Cont. (-) and Internal Control, 770 bp, lane 3; Buffer Control, lane 4; Reference strain *B. melitensis* biotype 3 (Ether-ATCC 23458), lanes 5; *Brucella* isolate from ram.

Table. Dehydrated culture media and supplementary reagents for routine diagnosis used in this study.

Culture media & supplements	Brand-Catalog number
Colombia Agar (7% defibrinated sheep blood)	BD®- COS 43041
MacConkey Agar	Oxoid®- CM0115
Levine Eosin Methylene Blue Agar	Oxoid®- CM0069B
Brucella Selective Medium Base	Oxoid®-CM0169
Brucella Selective Supplement	Oxoid® SR0083
Listeria Selective Agar	Oxoid®-CM0856B
Listeria Selective Supplement	Oxoid®-SR0141E
Butzler Selective Medium (Colombia Blood Agar Base)	Oxoid®-CM0331B
Butzler- Campylobacter Selective Supplement	Oxoid®- SR-0085E
XLT-4 Agar Base	BD, Difco®- 223420
XLT-4 Supplement	BD Difco™-100 mL
Sabouraud Dextrose Agar	Oxoid®- CM0041B

3. Results and discussion

Microscopically, the outline of the enlarged testis and seminiferous tubules was retained, while the seminal epithelium was necrotic and desquamated (Figure 1c). Central areas of the inflammatory foci contained abundant granular to flocculent eosinophilic cellular debris admixed with degenerate neutrophils and macrophages. Multifocal mononuclear cell infiltrates surrounded and separated the tubules. Epididymis revealed multifocal pyogranulomas effacing normal tubular architecture. Hyperplasia and hydropic degeneration of tubular epithelium with intraepithelial luminal formations was seen. Interstitial areas were fibrotic and densely infiltrated with mononuclear inflammatory and giant cells.

Gram negative coccobacilli were seen after Gram staining, and red stained coccobacilli were seen after modified Ziehl Neelsen staining. *Brucella* spp. were isolated from the clinical samples including the liver, lung, kidneys, and brain. No colony growth was observed on other agar plates except for *Brucella* on Colombia Agar during the incubation period. The identification of the isolate was carried out by conventional biotyping procedures according to Alton (8) including differentiating Rev 1. After typing, the isolate was identified as *B. melitensis* biotype 3. The target sequence of a 460-bp band was observed after a *Brucella* genus-specific PCR assay (Figure 1d).

Infections of the accessory sex glands of males allow the dissemination of the organism through semen.

While chronically affected rams often have unilateral or bilateral atrophy with swelling and hardening of the epididymis (3), in this case the epididymis had a soft consistency due to pyogranuloma formation and the accumulation of fibrinopurulent exudate. Fibrinous fluid and fibrous adhesions may be present in epididymitis and orchitis cases caused by *Brucella* spp. The quantity of fibrinous exudate in this case was significant. The presence of inflammatory cells in the ductus epididymis could support the hypothesis of an ascending route of the infection.

There are limited studies about the biotypes of *B. melitensis* in rams (9). *Brucella melitensis* biovar 3 has been reported to be the predominant biovar in sheep in Turkey (10–12). The present report describes a case of epididymitis and orchitis in a ram caused by *B. melitensis* biovar 3 determined by histopathology, microbiology, and PCR. The isolation of *B. melitensis* from a case of ovine orchitis is of epidemiological value and shows the importance of this agent in the etiology of ovine and human brucellosis in Turkey (13,14). This will help establish a base for new research to understand the *Brucella* biovars in this region, and to develop relevant control strategies for this very important zoonosis.

Acknowledgments

The authors would like to thank Dr Neil Dyer and Dr İ Taci Cangül for their editorial help.

References

1. Corbel, M.J.: Brucellosis in humans and animals. World Health Organization. Chapter 3, Epidemiology of brucellosis in humans, Brucellosis in Humans and Animals. pp. 13–19, Albany, NY, USA: World Health Organization, 2006. <http://www.who.int/csr/resources/publications/Brucellosis.pdf> (accessed on 09.01.2012).
2. Songer, J.G., Post, K.W.: The genus *Brucella*. In: Veterinary Microbiology, Bacterial and Fungal Agents of Animal Disease, Chapter 25, pp: 200–207. Elsevier Saunders, USA, 2005.
3. Quinn, P.J., Markey, B.K., Carter, M.E., Donnelly, W.J., Leonard, F.C.: *Brucella* species. In: Veterinary Microbiology and Microbial Disease, Chapter 28, Blackwell Publishing, MPG Books Ltd., pp: 162–167. Bodmin, Cornwall, UK, 2002.
4. O.I.E.: Terrestrial Manual 2009, Chapter 2.7.2. Caprine and ovine brucellosis (excluding *Brucella ovis*). http://www.oie.int/fileadmin/Home/eng/Health_standards/tahm/2.07.02_CAPRINE_OVINE_BRUC.pdf, 2009 (accessed on 09.01.2012).
5. Ferreras, M.C., Munoz, M., Perez, V., Benavides, J., Garcia-Pariente, C., Fuertes, M., Aduriz, G., Garcia-Marin, J.F.: Unilateral orchitis and epididymitis caused by *Salmonella enterica* subspecies *diarizonae* infection in a ram. J. Vet. Diagn. Invest. 2007; 19: 194–197.
6. Jansen, B.C.: The etiology of ram epididymitis. Onderstepoort J. Vet. 1980; 47: 101–107.
7. Büyükcangaz, E., Sen, A., Carli, K.T., Kahya, S.: Comparison of direct culture versus PCR for the detection of *Brucella* in aborted fetuses of cattle and sheep in Turkey. Vet. Rec. 2011; 168: 430.
8. Alton, G., Jones, L.M., Angus, R.D., Verger, J.M.: Bacteriological methods. In: Techniques for the Brucellosis Laboratory. INRA, 1988; pp 13–61.
9. Chand, P., Sadana, J.R., Malhotra, A.K.: Epididymo-orchitis caused by *Brucella melitensis* in breeding rams in India. Vet. Rec. 2002; 50: 84–85.
10. Büyükcangaz, E., Şen, A., Kahya, S.: Isolation and biotyping of *Brucella melitensis* from aborted sheep and goat fetuses. Turk. J. Vet. Anim. Sci. 2009; 33: 311–316.
11. Erdenliğ, S., Şen, A.: Isolation and biotyping of *Brucella* species from aborted sheep fetuses. J. Pen. Vet. Microbiol. 2000; 31: 31–42. (In Turkish)

12. Erdenliđ, S., Baklan E.A., Aksoy H.Y.: The identification, characterization and distribution of *Brucella* isolates in Turkey in the last two years, 2007 to 2008. VLA International Conference - Animal Diseases, 2-4 September, Royal Holloway, University of London UK, 2009.
13. Scientific Committee on Animal Health and Animal Welfare: 2001, European Commission, Brucellosis in sheep and goats (*Brucella melitensis*). http://ec.europa.eu/food/fs/sc/scah/out59_en.pdf (accessed on 09.01.2012).
14. ŐimŐek, H., Erdenliđ, S., Oral, B., Tlek, N.: Typing and biotyping of *Brucella* isolates of human origin and their epidemiologic evaluation *Klimik Derg.* 2004; 17: 103-106. (In Turkish)